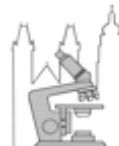


# Případ č. 9

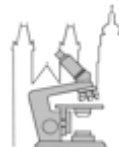Hana Faistová



# případ č. 9

## Klinické údaje

- 67 let 
- Sledována pro ca prsu před 13 lety
- Nyní elevace onkomarkerů
- Na PET/CT ložisko s blízkým vztahem k VMS



# případ č. 9

## Makropopis

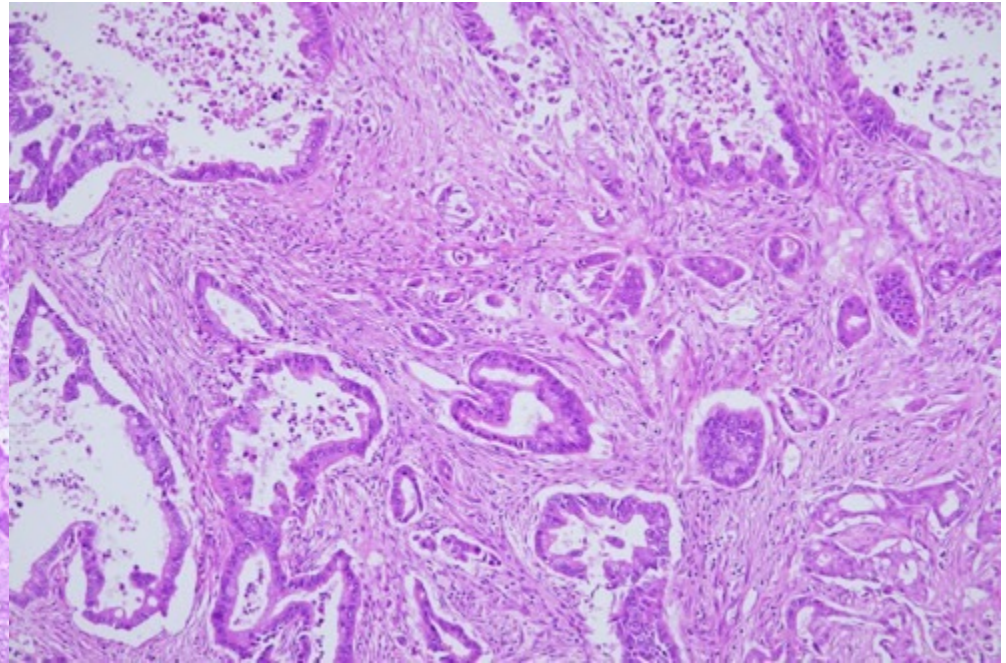
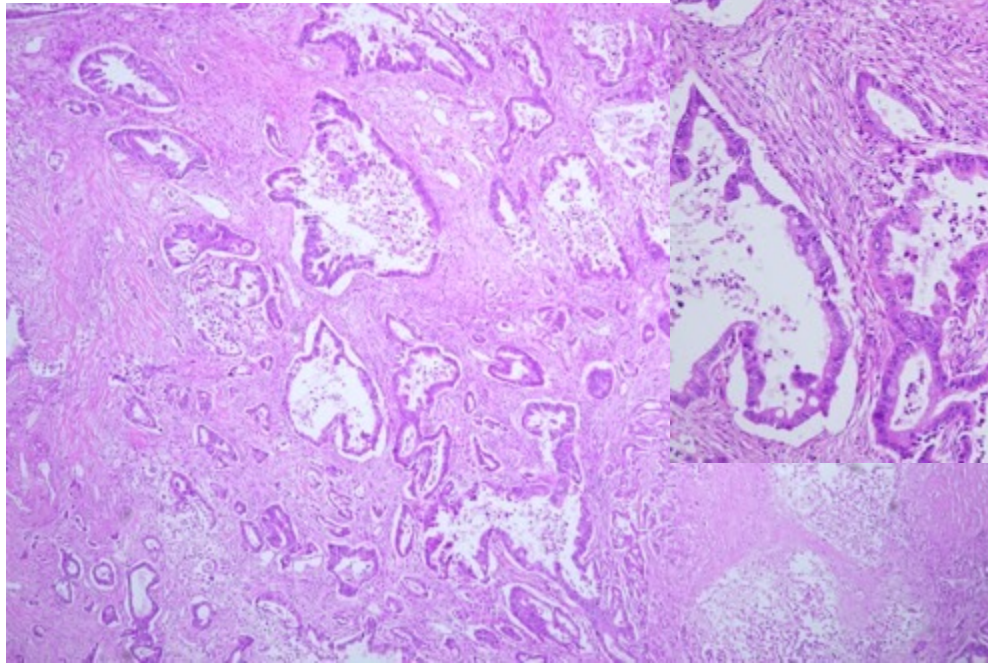
- Levostranná resekce pankreatu
- Tu pankreatu 35 mm
- Slezina 165 x 110 x 45 mm
  - Pod pouzdem tmavě fialový uzel průměru 14 mm
- Přídavná slezina průměru 8 mm



# případ č. 9

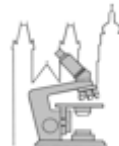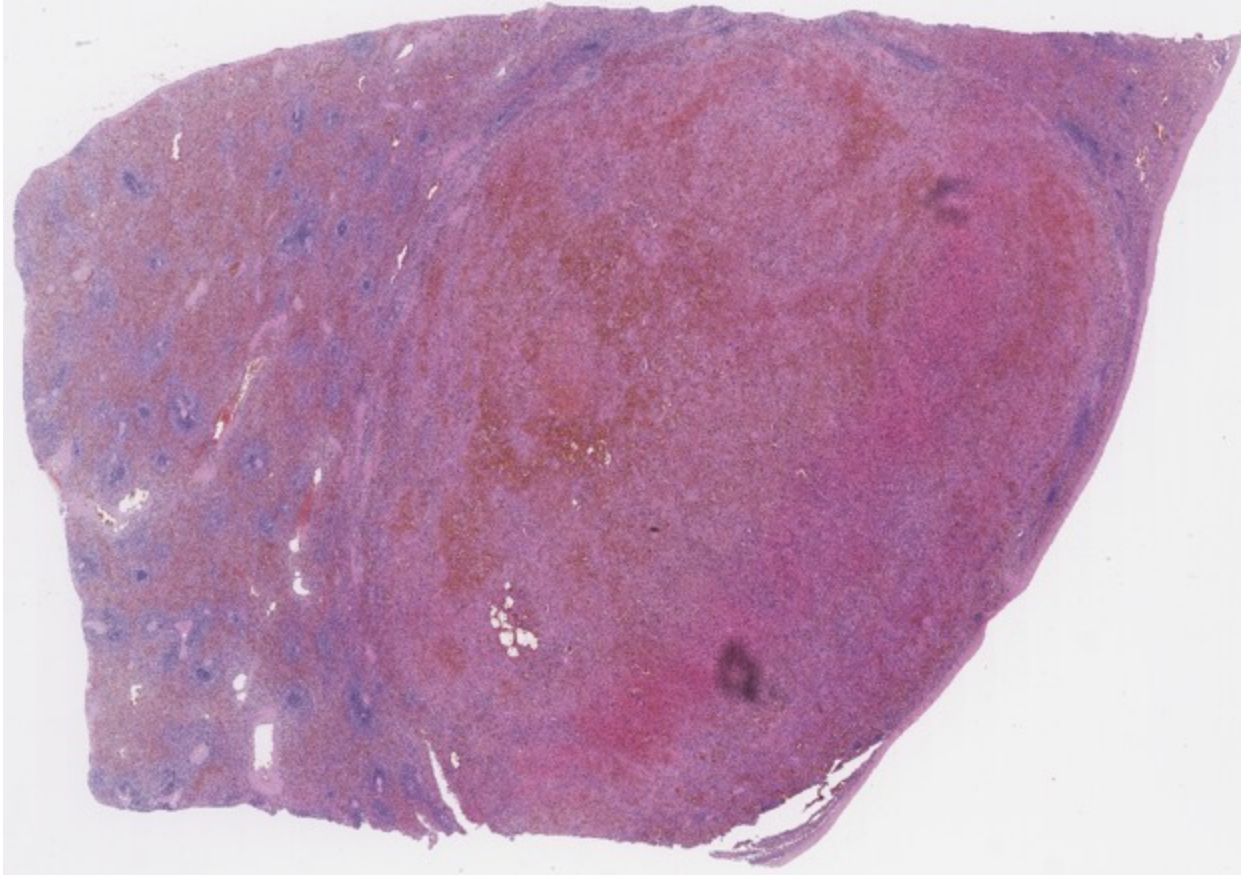
## Mikropopis

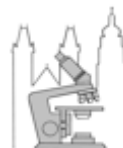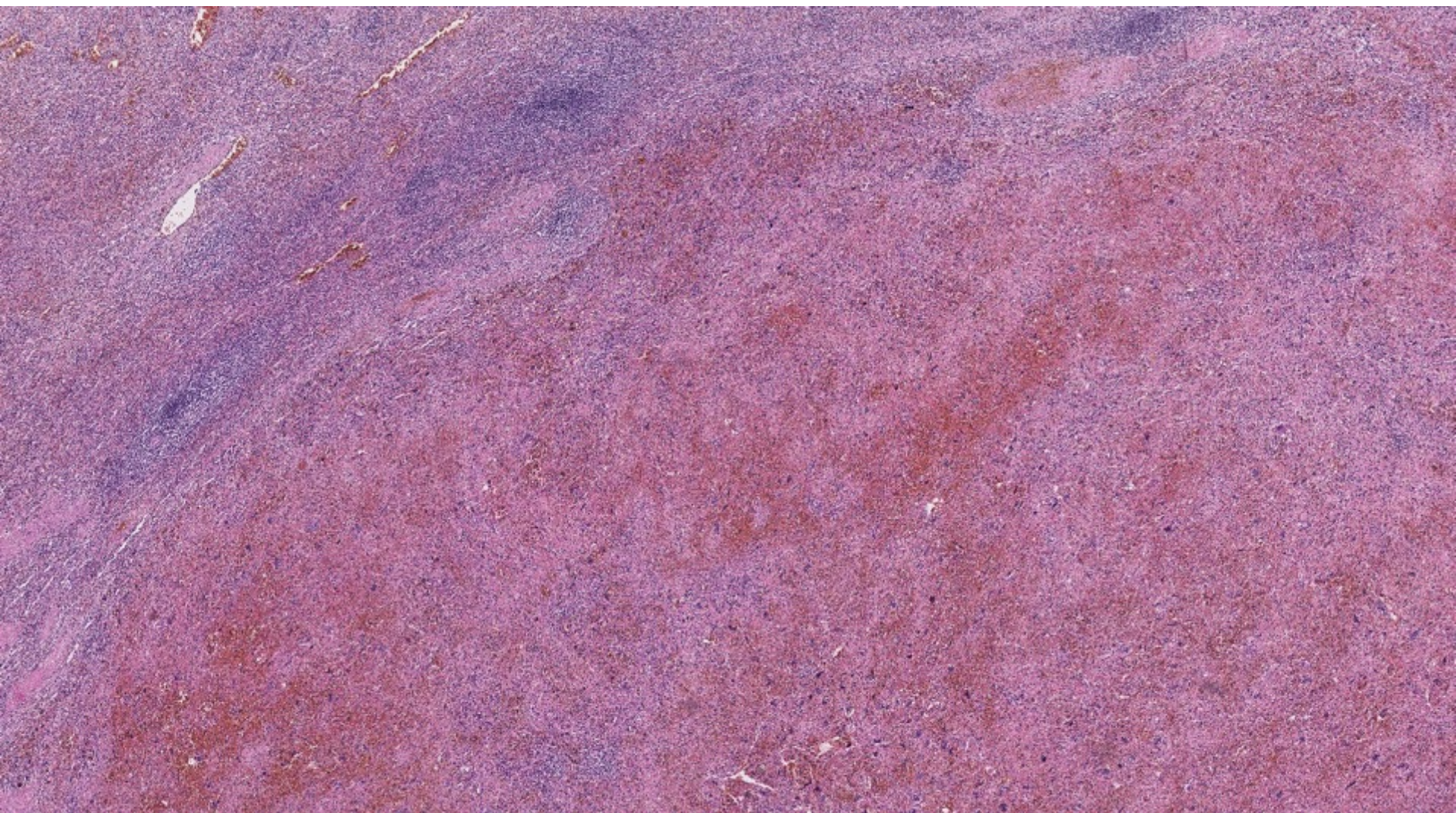
N1 (9/34); infiltrace cév

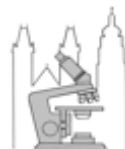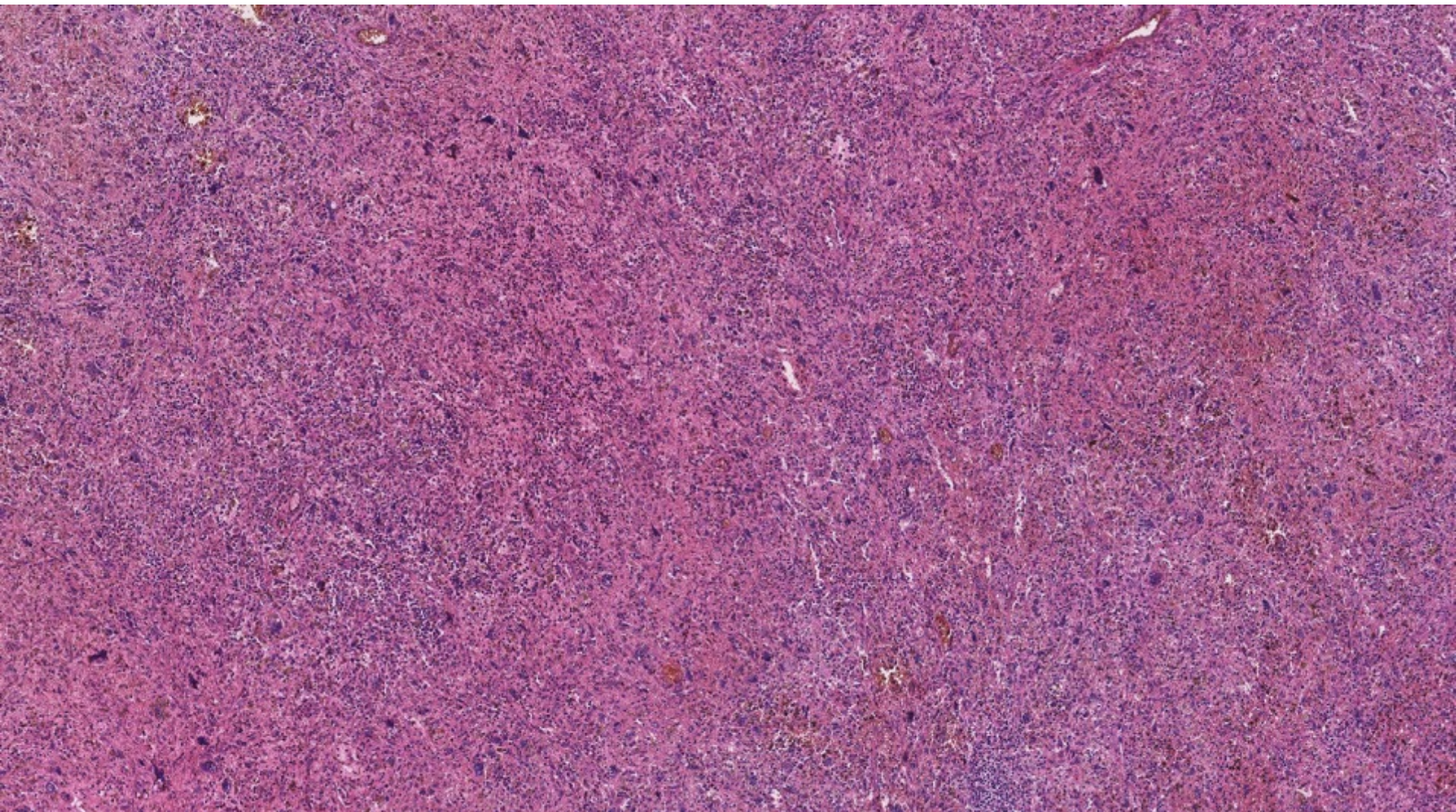


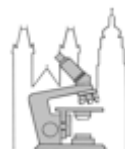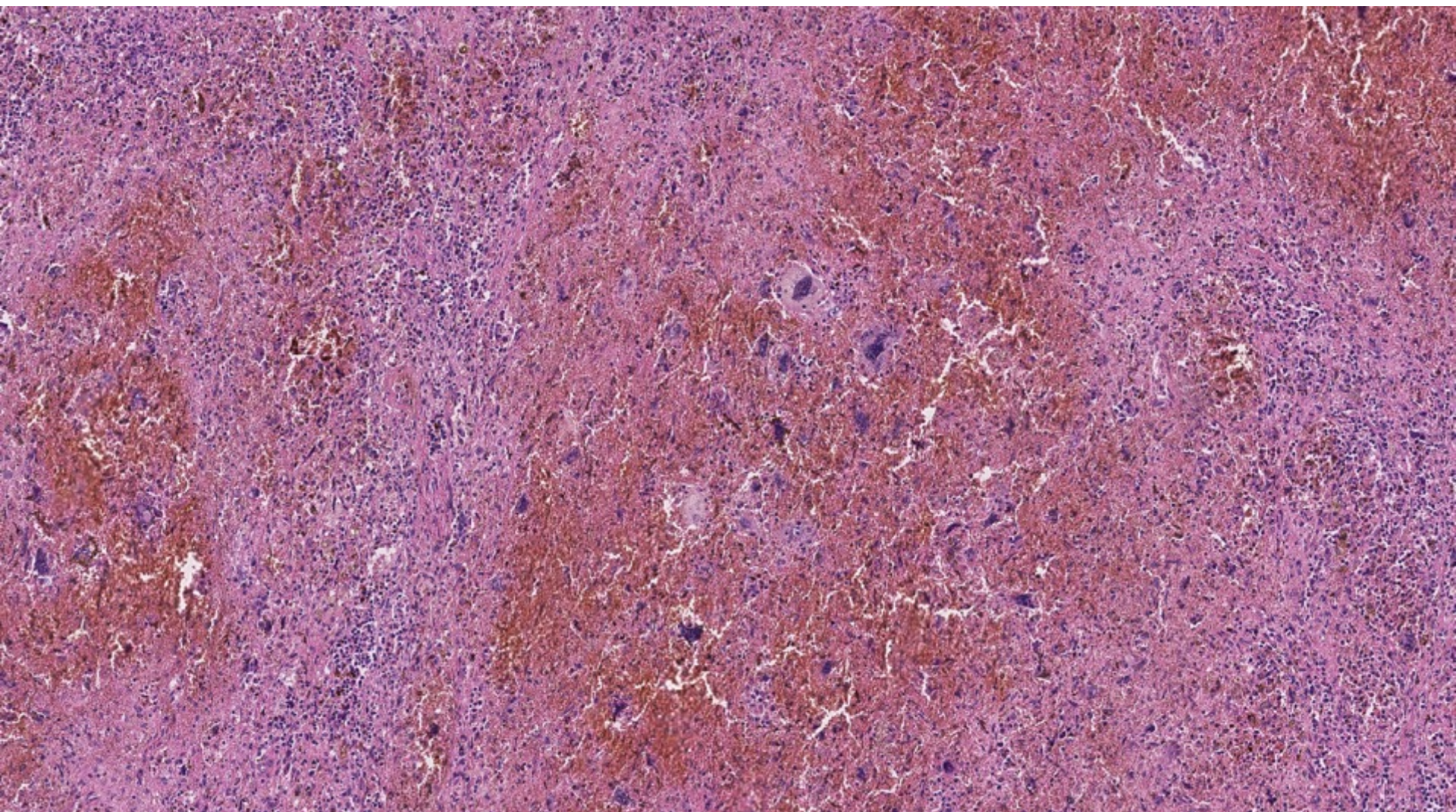
# případ č. 9

## Mikropopis

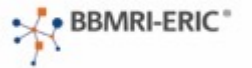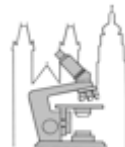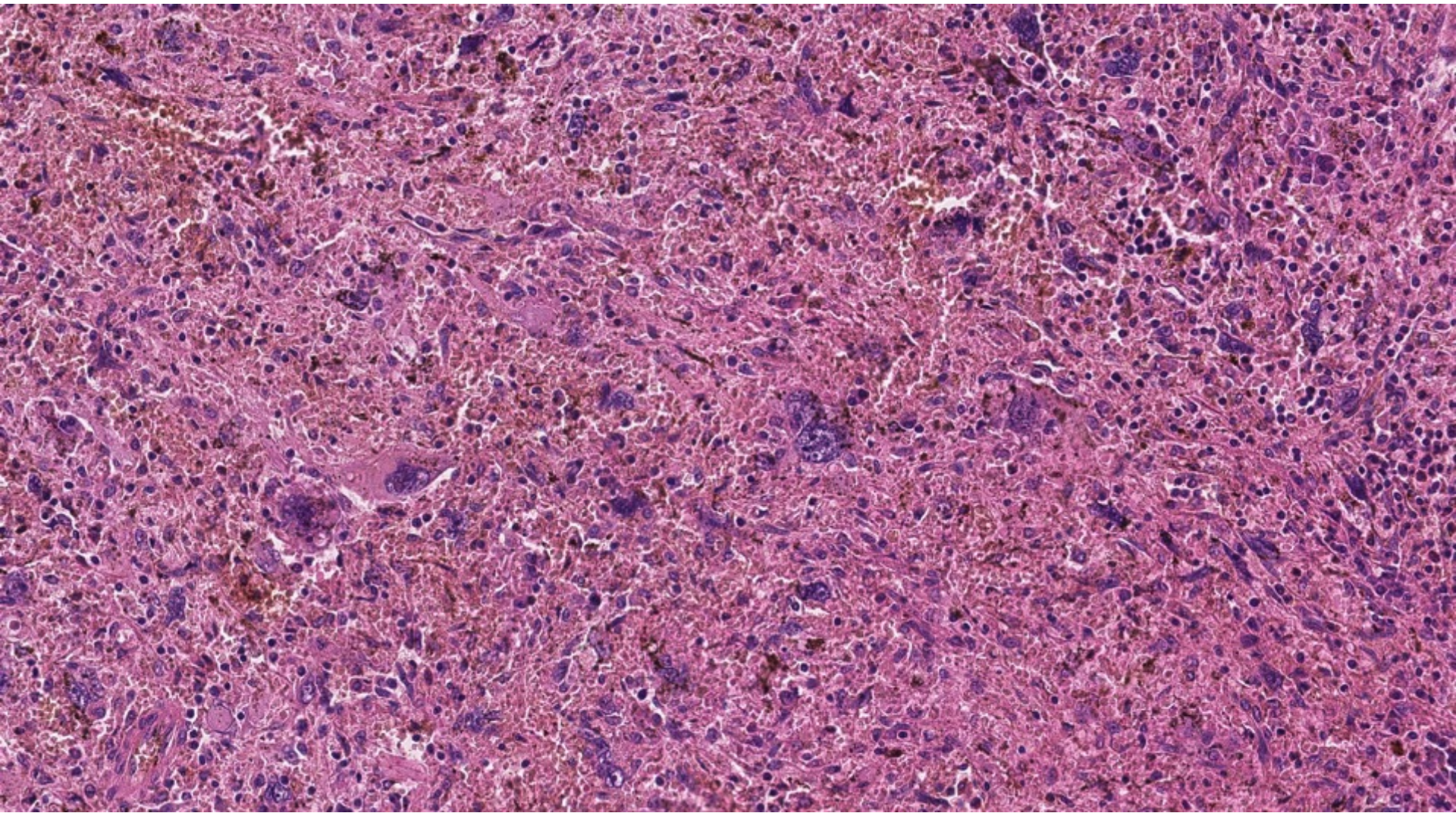


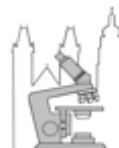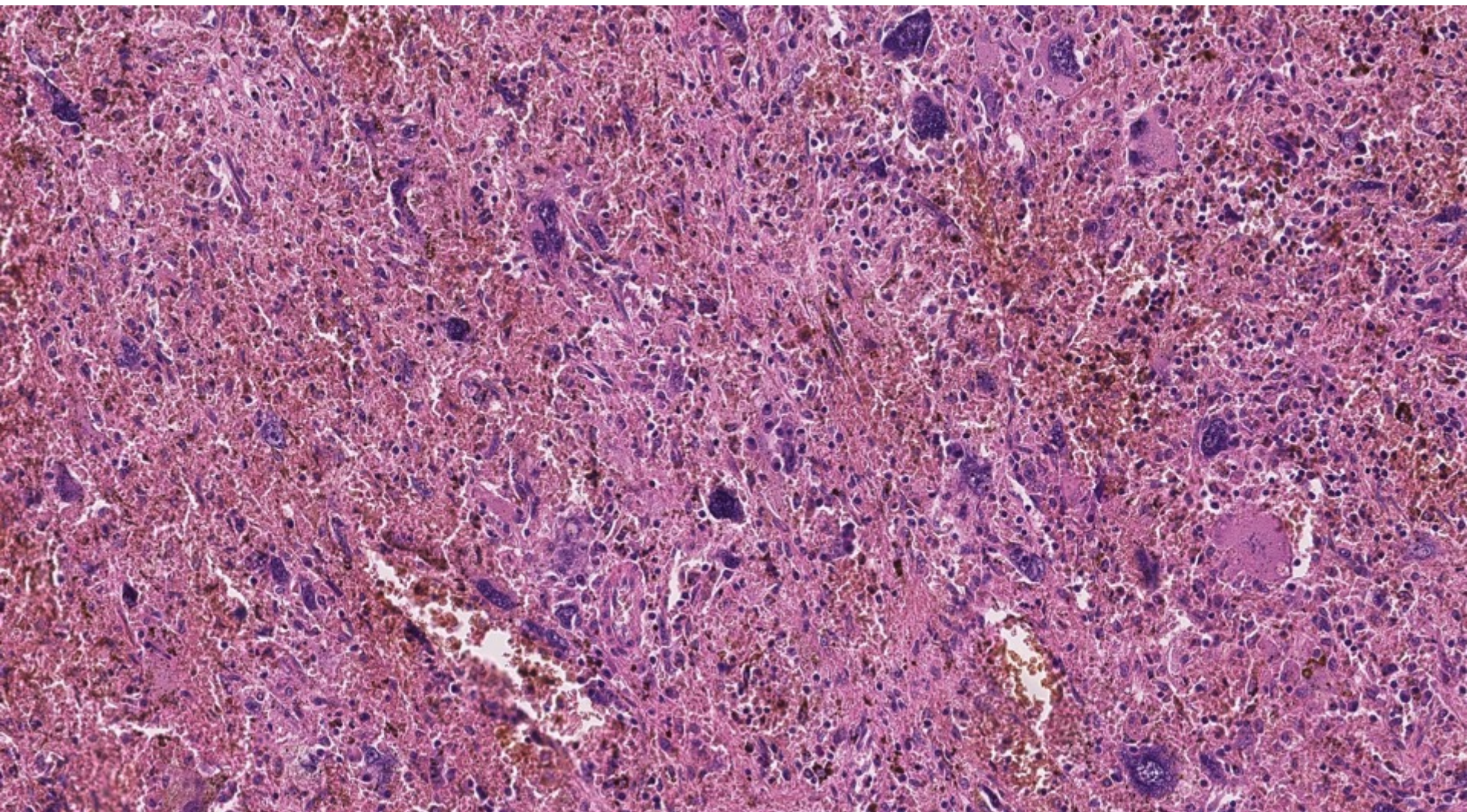







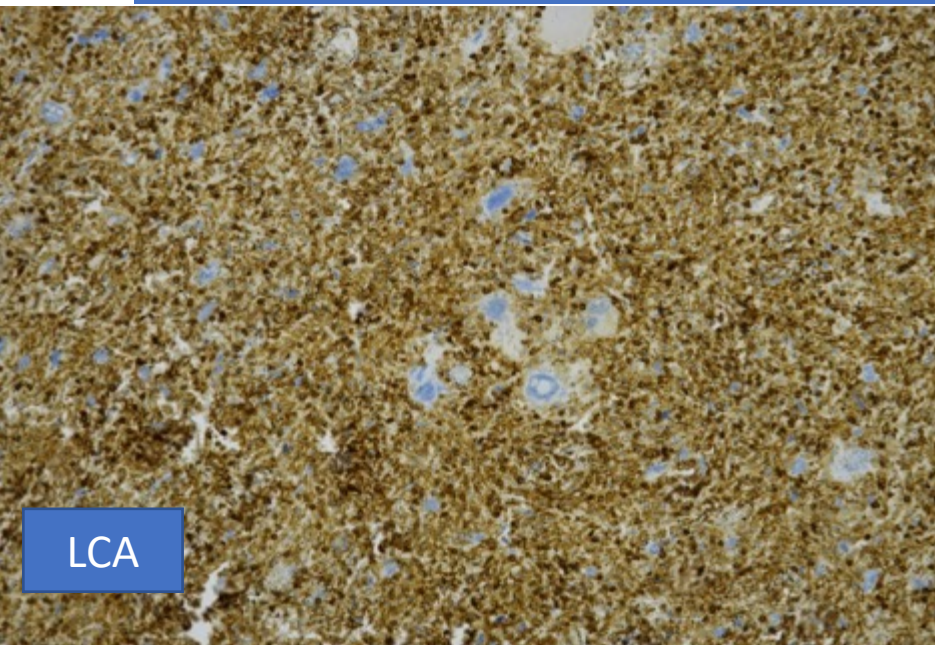






# případ č. 9

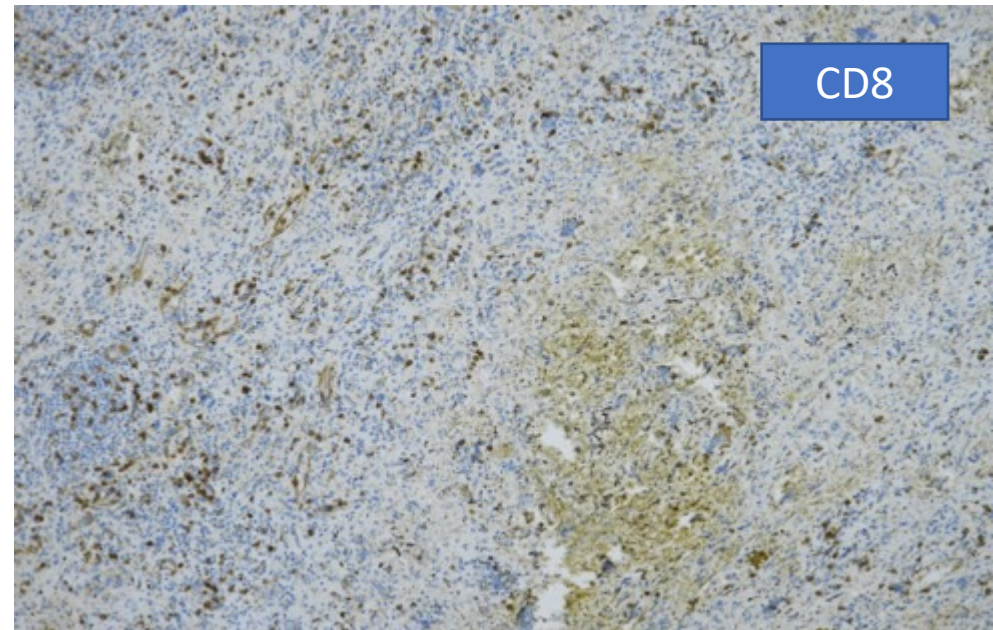
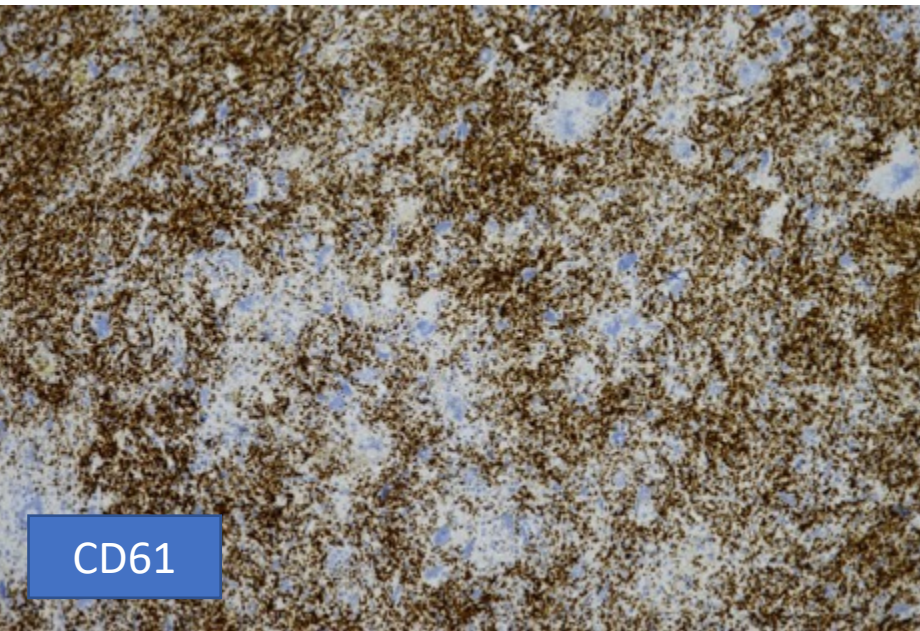
## Imunohistochemie





# případ č. 9

## Imunohistochemie



# případ č. 9

## Diagnóza

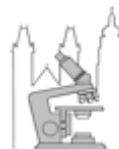# Hamartom s bizarními buňkami

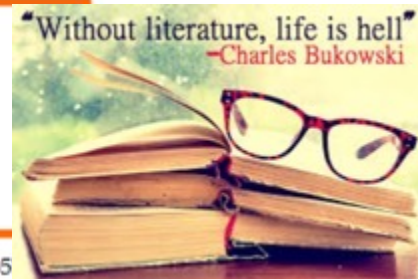


# případ č. 9

## „Splenom“

- Podkladem výstelka sinů
- Malformace x posttraumatická reaktivní proliferace x neoplázie
- Incidentální / autoptický náález
- Incidence 0,1 %
- Všechny věkové / genderové kategorie
- Dezorganizované štěrbinovité cévní prostory
  - + Adipocyty
  - + Extramedulární hematopoéza
  - Cystická degenerace (CT znak)
  - **CD8+**, CD68+, CD34+-
- Bez bílé pulpy

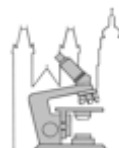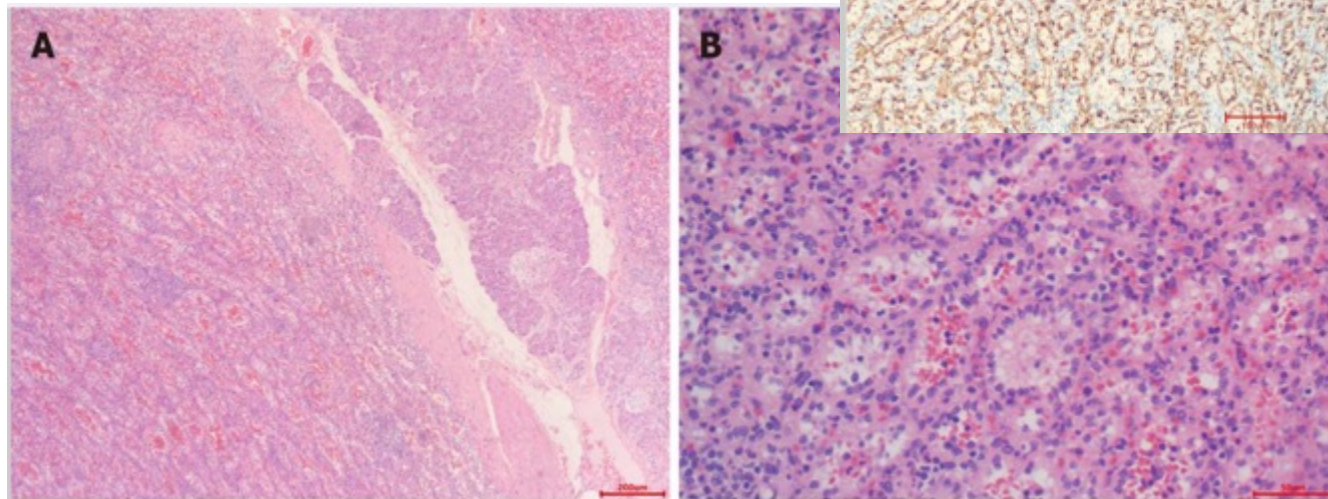




CASE REPORT

Successful treatment of pancreatic accessory splenic hamartoma by laparoscopic spleen-preserving distal pancreatectomy: A case report

Shao-Yan Xu, Bo Zhou, Shu-Mei Wei, Ya-Nan Zhao, Sheng Yan





# případ č. 9

## Diskuze



Case report



### Splenic hamartoma associated with thrombocytopenia: A case report



International Journal of Surgery Case Reports

Volume 10, 2017, Pages 172-175



[Toshiaki Komo](#)<sup>a</sup>, [Jun Hihara](#)<sup>a</sup>  , [Mikihiro Kanou](#)<sup>a</sup>, [Toshihiko Kohashi](#)<sup>a,c</sup>, [Ichiro Ohmori](#)<sup>a,c</sup>, [Masanori Yoshimitsu](#)<sup>a,c</sup>, [Takuhiro Ikeda](#)<sup>a</sup>, [Akira Nakashima](#)<sup>a</sup>, [Masashi Miguchi](#)<sup>a,c</sup>, [Ichiko Yamakita](#)<sup>a</sup>, [Hidenori Mukaida](#)<sup>a</sup>, [Naoki Hirabayashi](#)<sup>a</sup>, [Mayumi Kaneko](#)<sup>b</sup>

Carlomagno et al. *Journal of Medical Case Reports* (2015) 9:154  
DOI 10.1186/s13256-015-0627-3



JOURNAL OF MEDICAL  
CASE REPORTS

CASE REPORT

Open Access

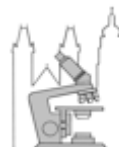### Multiple splenic hamartomas and familial adenomatous polyposis: a case report and review of the literature



Nicola Carlomagno<sup>1\*</sup>, Francesca Duraturo<sup>2</sup>, Maria Candida<sup>1</sup>, Marina De Rosa<sup>2</sup>, Valeria Varone<sup>3</sup>, Giuseppe Ciancia<sup>3</sup>, Armando Calogero<sup>1</sup> and Michele L Santangelo<sup>1</sup>

### Incidentally discovered asymptomatic splenic hamartoma misdiagnosed as an aneurysm: A case report

Xue-Feng Cao, Li-Peng Yang, Song-Song Fan, Qiang Wei, Xu-Tao Lin, Xing-Yuan Zhang, Ling-Qun Kong



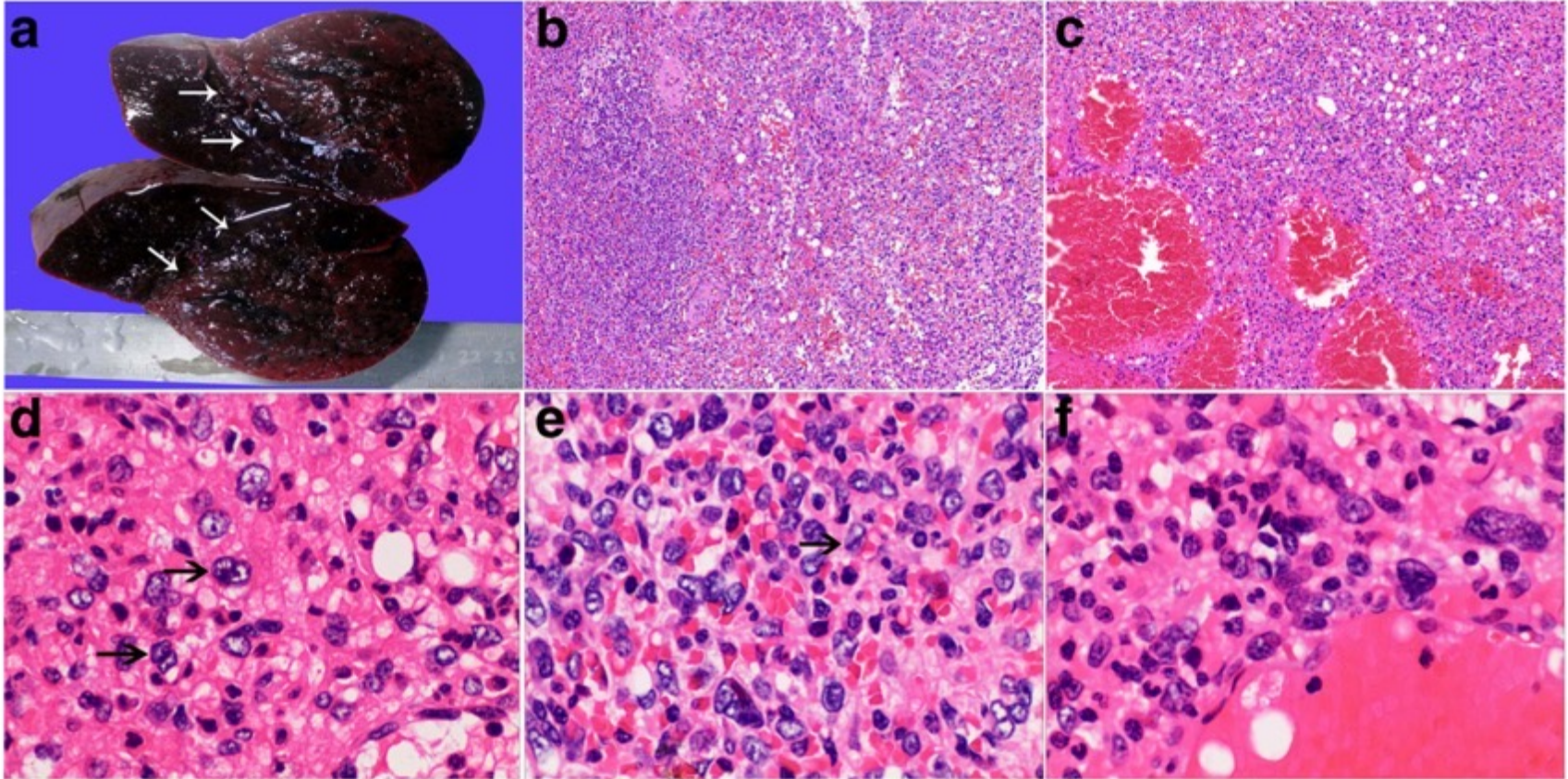
# případ č. 9

## Diskuze



Cheng et al. *Diagnostic Pathology* (2018) 13:8

Diagnostic Pathology



unencapsulated, round dark red colored and solid mass back pain

Abbreviations: NED no evidence of disease, NM not mentioned

stromal cells. Only six cases have been described in the literature. Proper identification is important to secure adequate treatment.

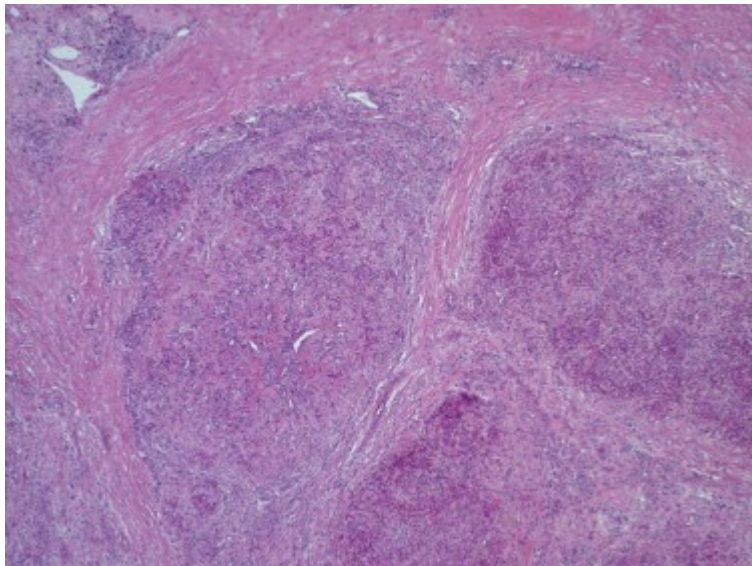
# případ č. 9

## Dif. dg.



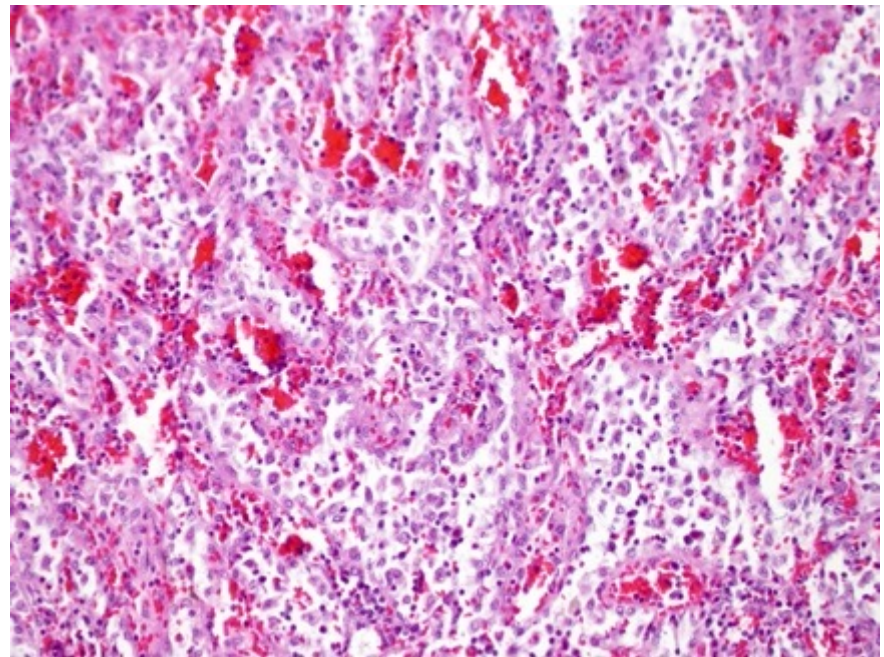
### Sklerozující angiomatoidní nodulární transformace

- Různé typy cév
- Sklerotizace, nodulární růst



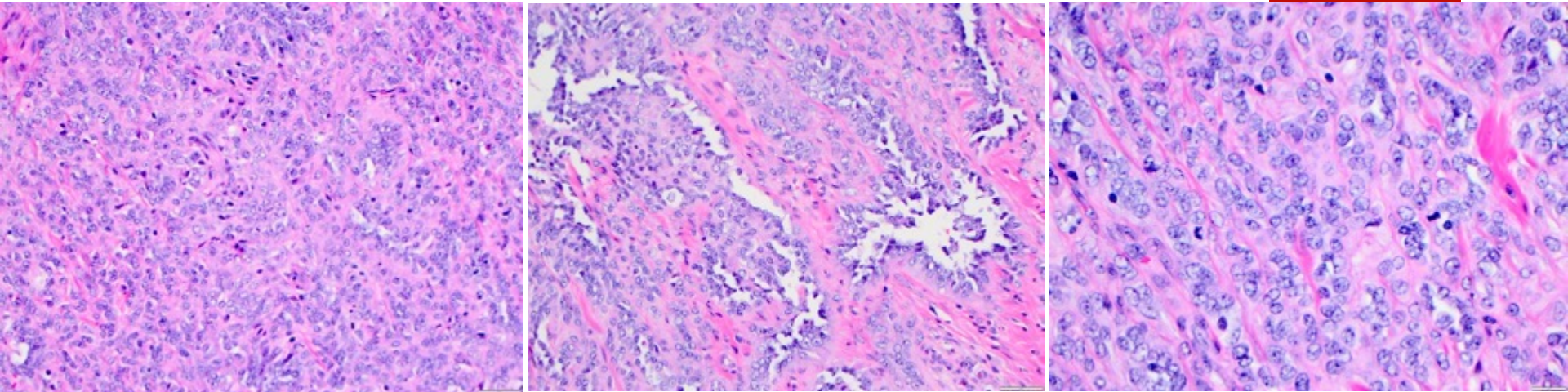
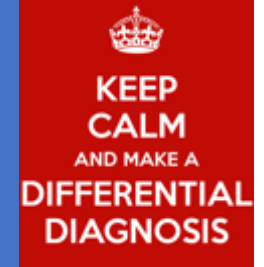### Angiom z litorálních buněk

- CD34, CD8, ERG neg.



# případ č. 9

## Dif. dg.



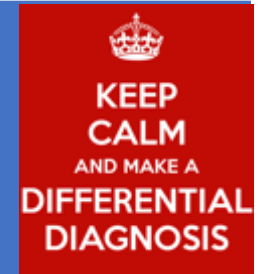## Angiosarkom

- Výrazné atypie
- Mitózy
- Značně agresivní



# případ č. 9

## Dif. dg.



Received: 30 August 2020 | Revised: 31 October 2020 | Accepted: 4 November 2020

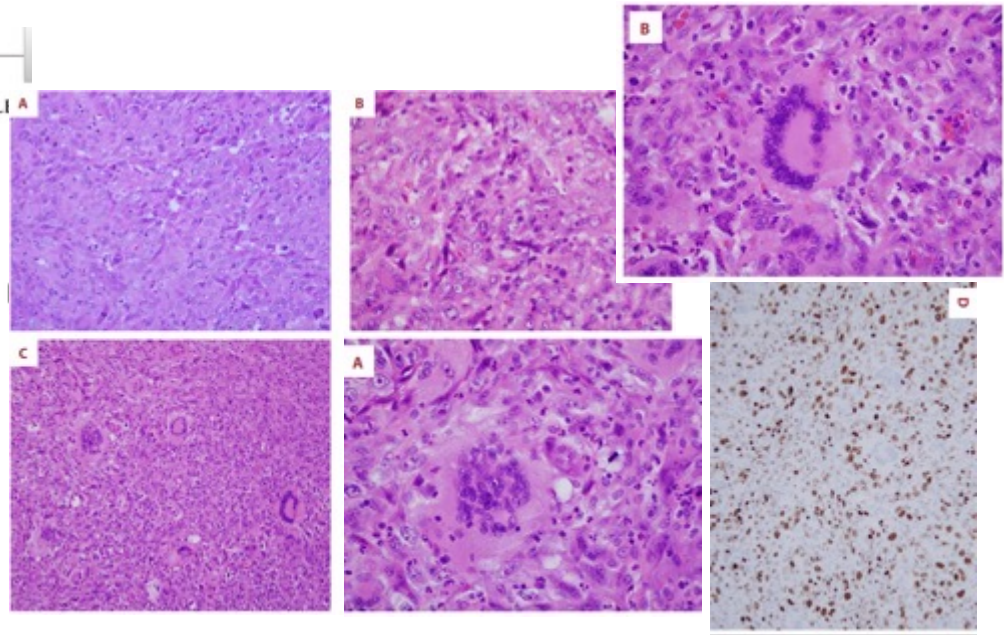
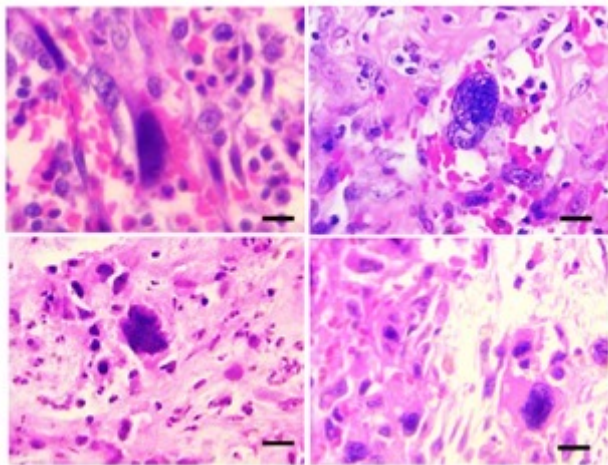
DOI: 10.1111/eas.14726

ORIGINAL ARTICLE

Cancer Science WILEY

### Bizarre giant cells in human angiosarcoma exhibit chemoresistance and contribute to poor survival outcomes

Grace Fangmin Tan<sup>1</sup> | Shane Goh<sup>2</sup> | Abner Herbert Lim<sup>2</sup> | Wei Liu<sup>2</sup> | Jing Yi Lee<sup>2</sup> | Vikneswari Rajasegaran<sup>2</sup> | Xin Xiu Sam<sup>3</sup> | Timothy Kwang Yong Tay<sup>3</sup> | Sathiyamoorthy Selvarajan<sup>3</sup> | Cedric Chuan-Young Ng<sup>2</sup> | Bin Tean Teh<sup>4,5,6,7,8</sup> | Jason Yongsheng Chan<sup>1,7,8</sup>



### Primary Urinary Bladder Angiosarcoma with Osteoclast-Like Multinucleated Giant Cells: A Case Report and Literature Review



ACEF 1 Nariman A. Nawar  
CDF 2 Jamie Olsen  
B 3 Tomislav M. Jelic  
D 3 Chun He

1 Department of Pathology, West Virginia University, Morgantown, WV, USA.  
2 Department of Urology, Charleston Area Medical Center, Charleston, WV, USA.  
3 Department of Pathology, Charleston Area Medical Center, Charleston, WV, USA.

