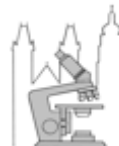

Případ č. 5

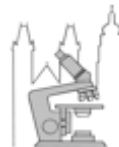Lucie Geryková

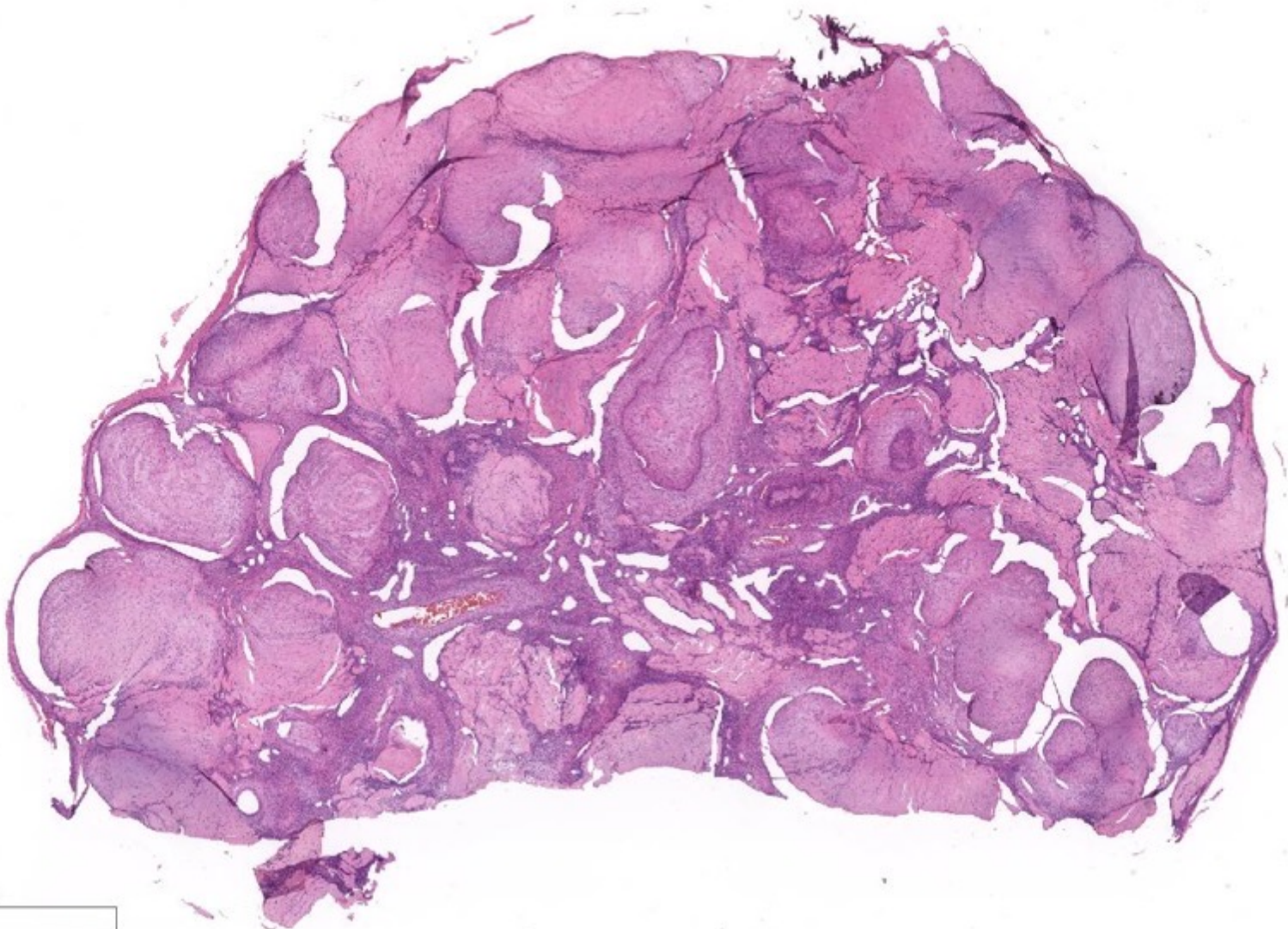


případ č. 5

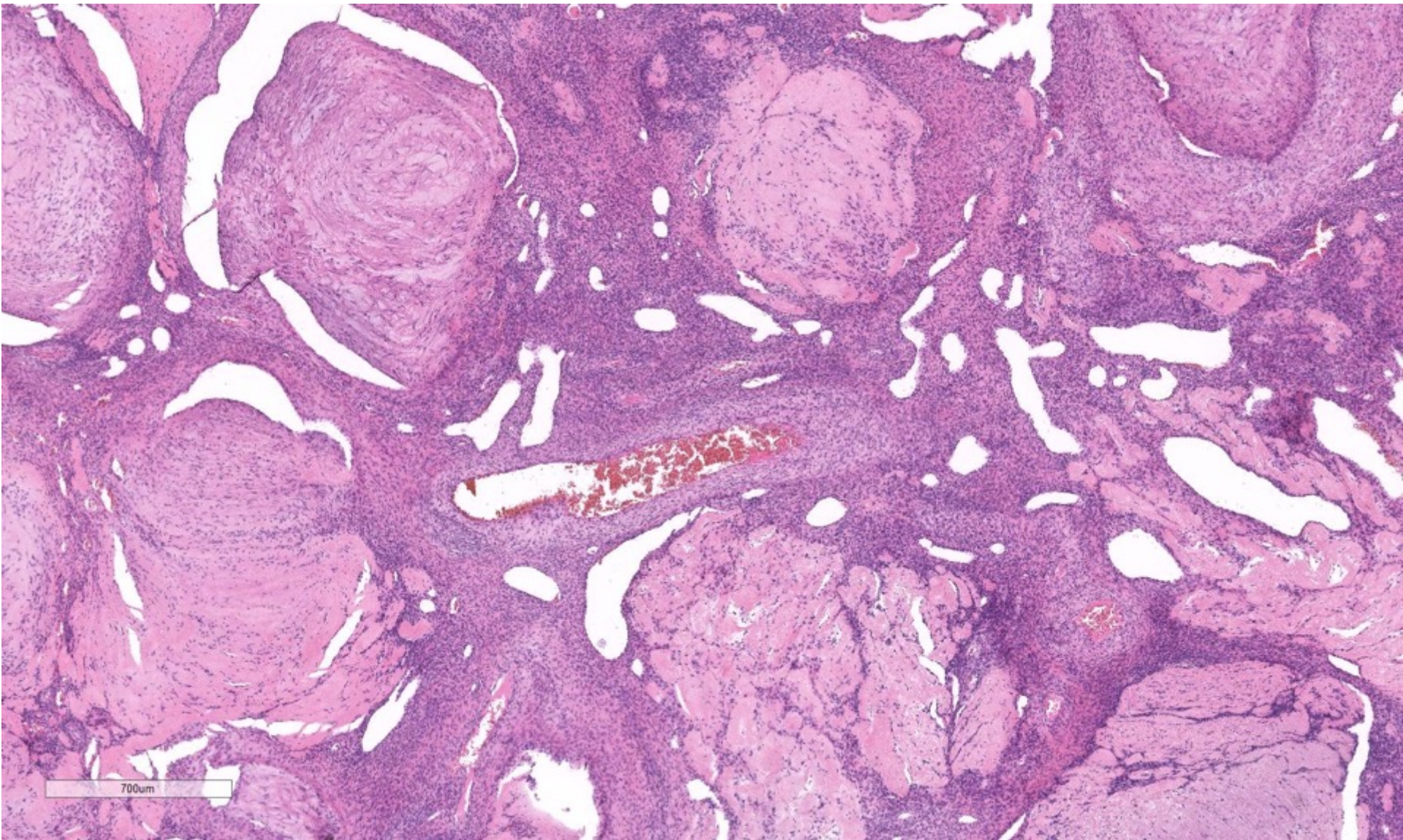
Klinické údaje & Makropopis

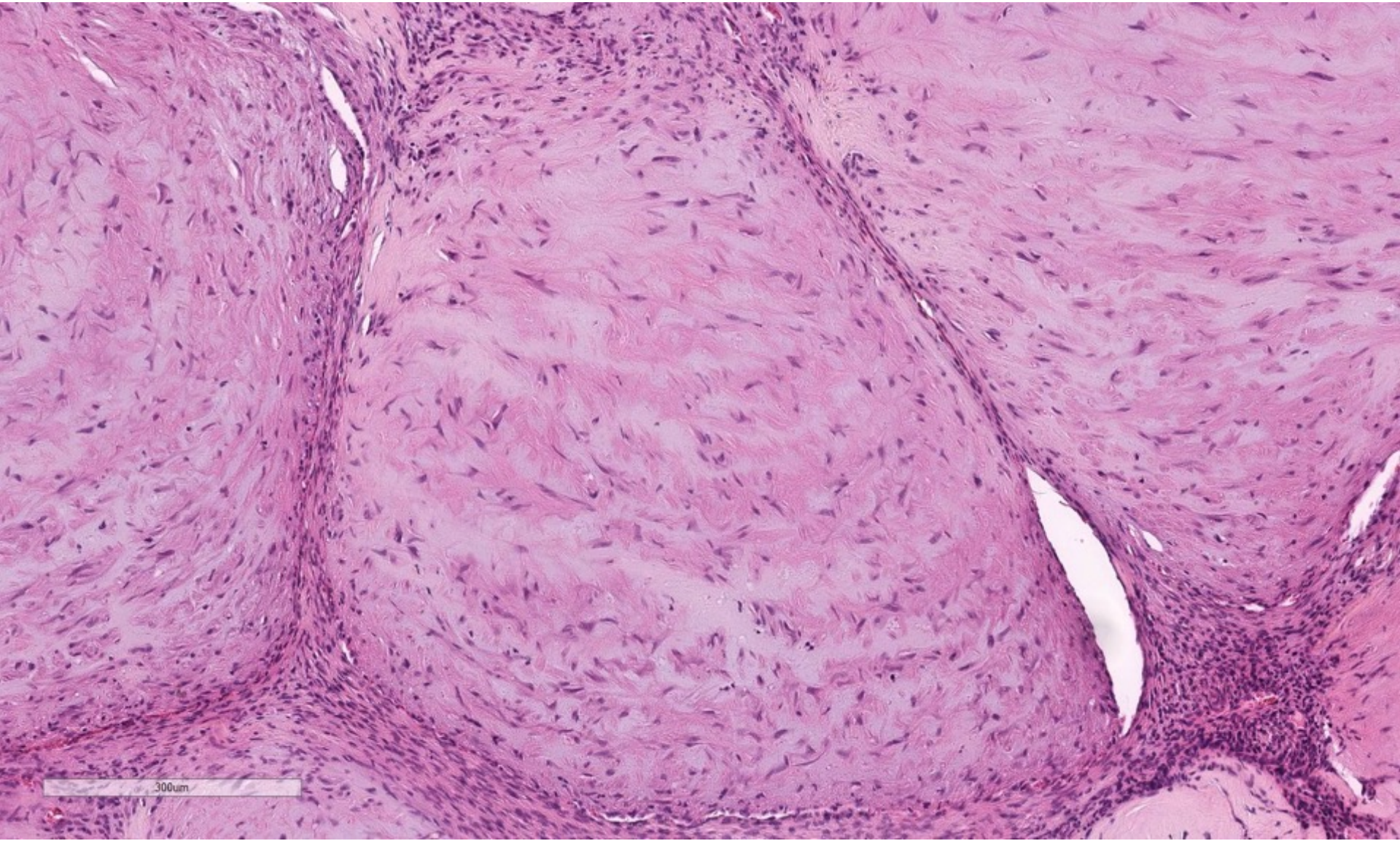
- pacient (55 let) s **exofytickým nodulárním tumorem kůže**
- konzultační vyšetření



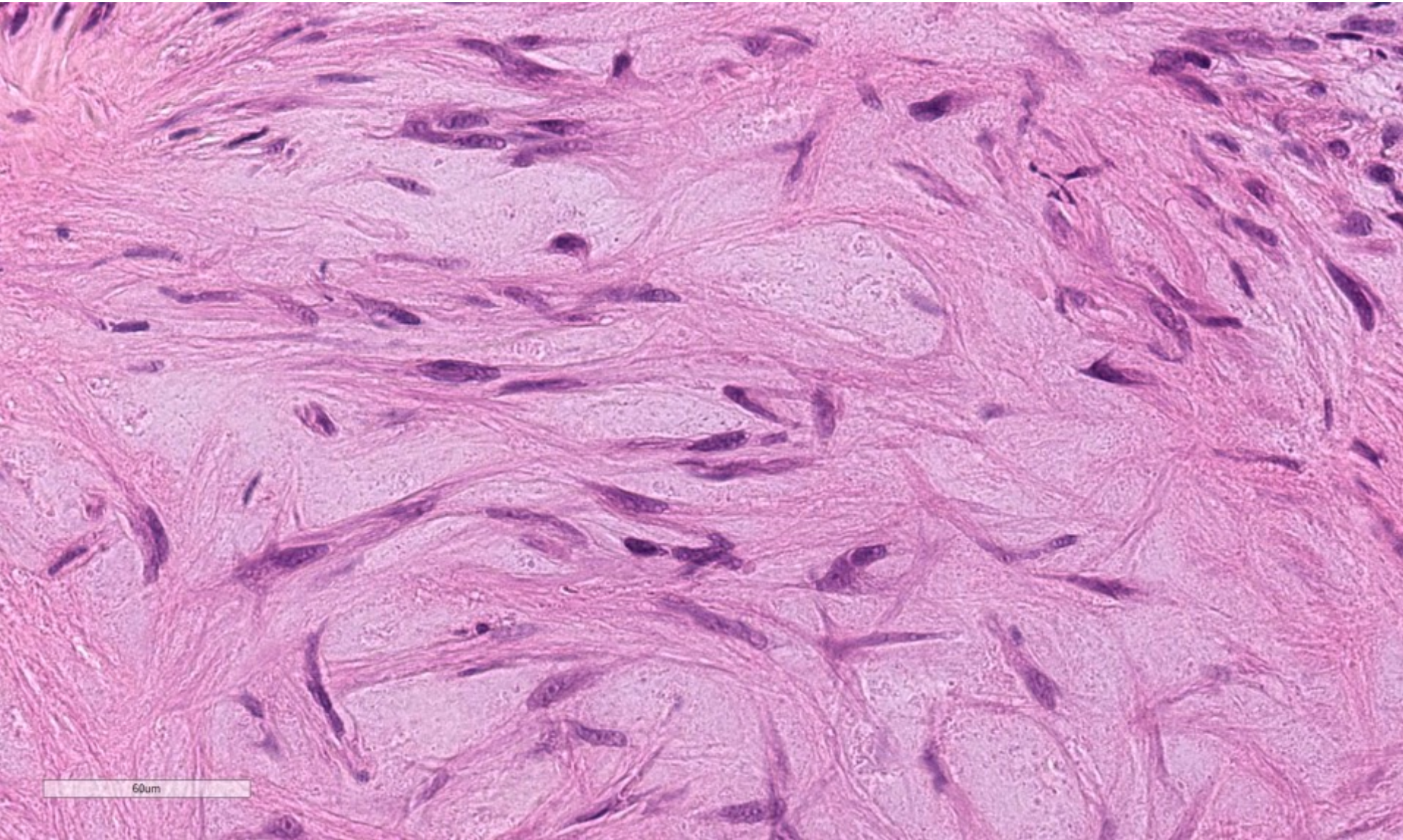


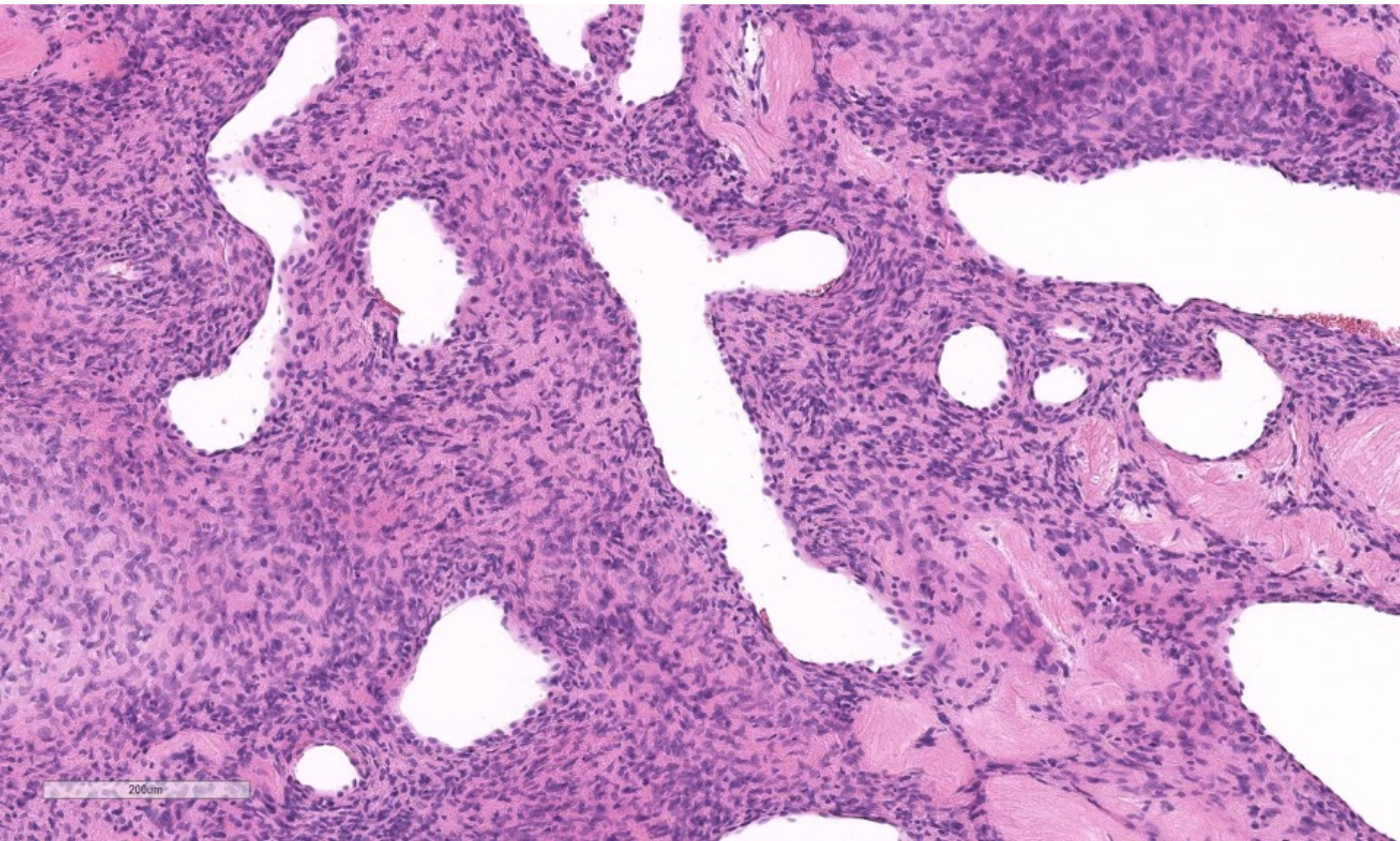
3mm



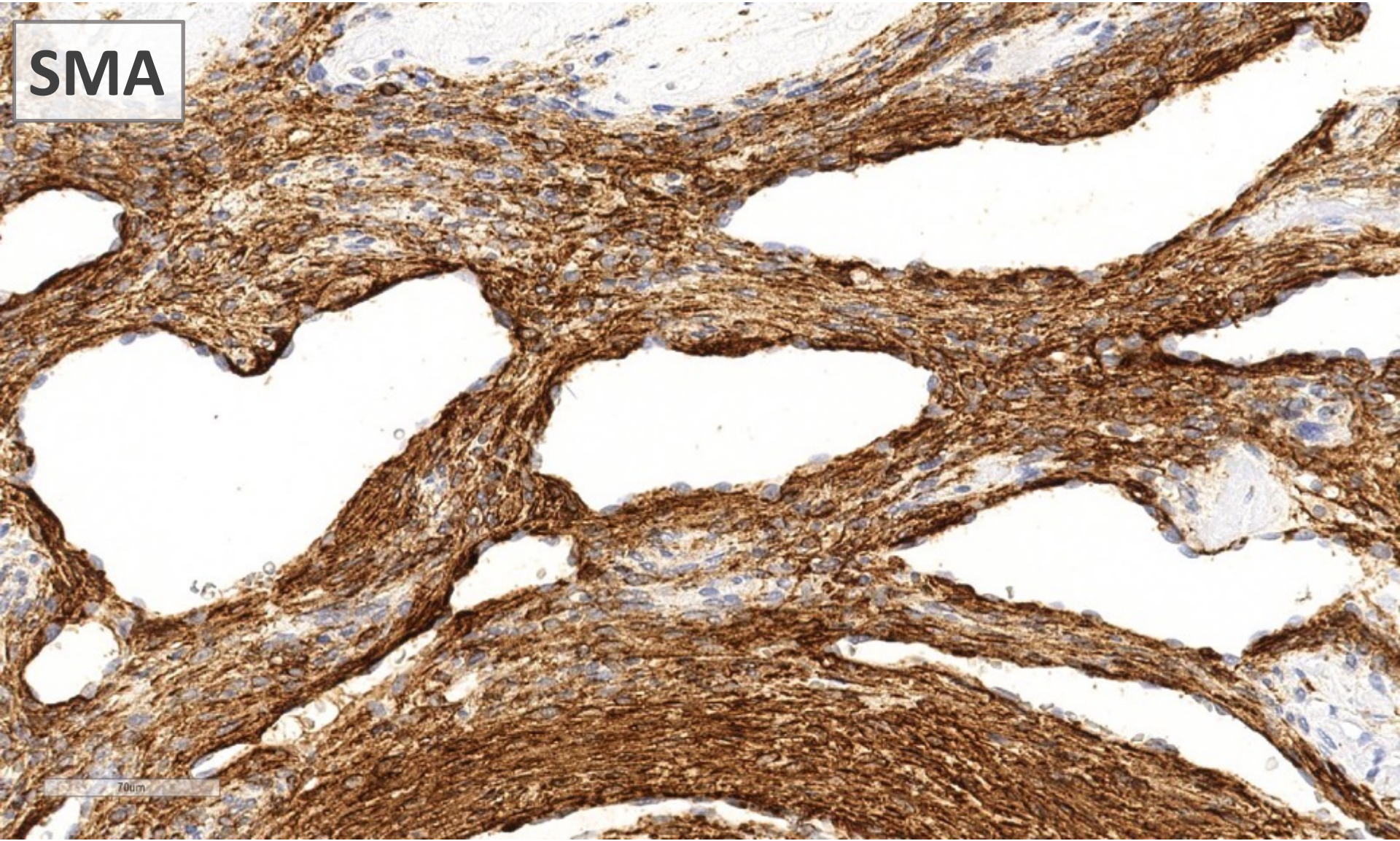


300um



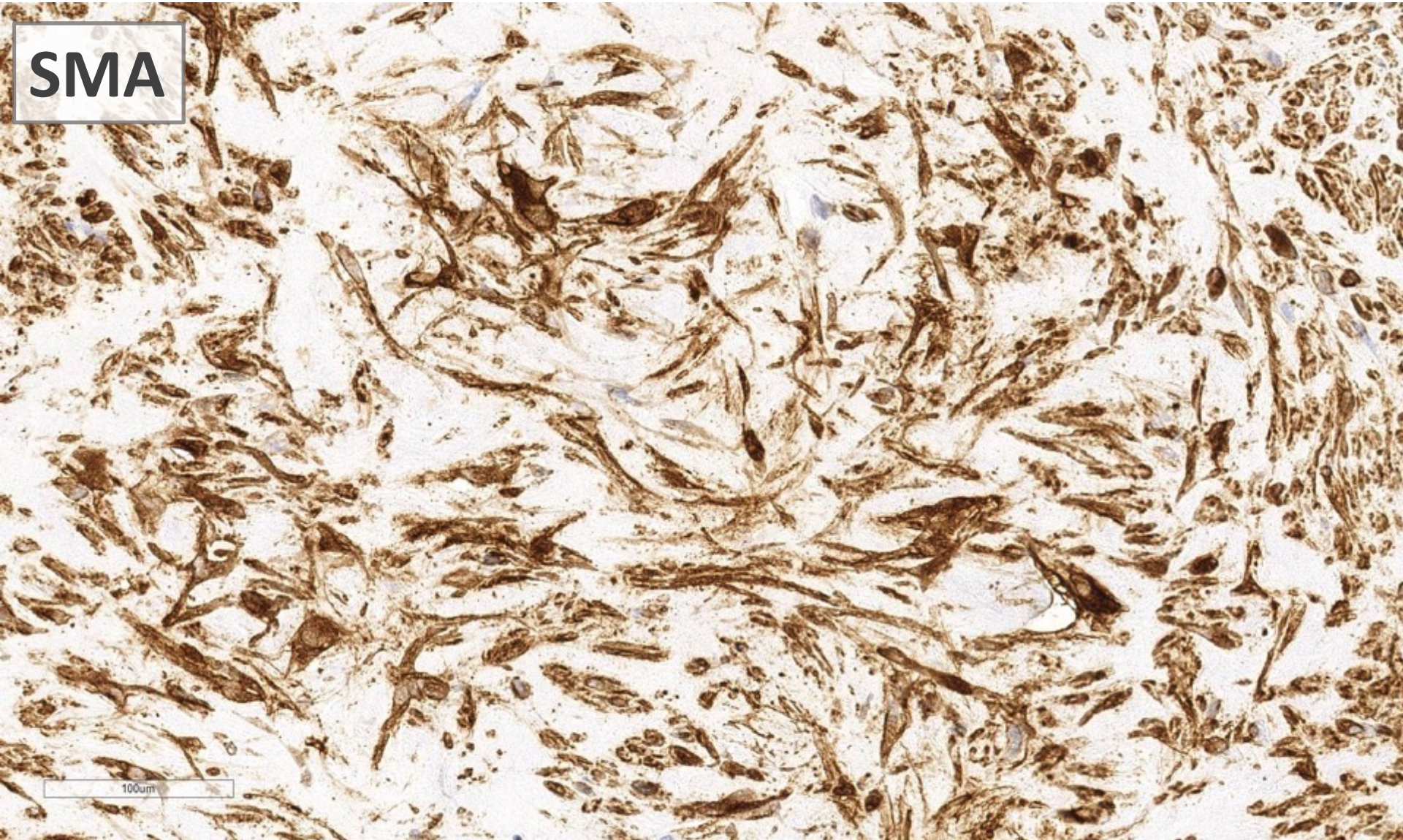


SMA



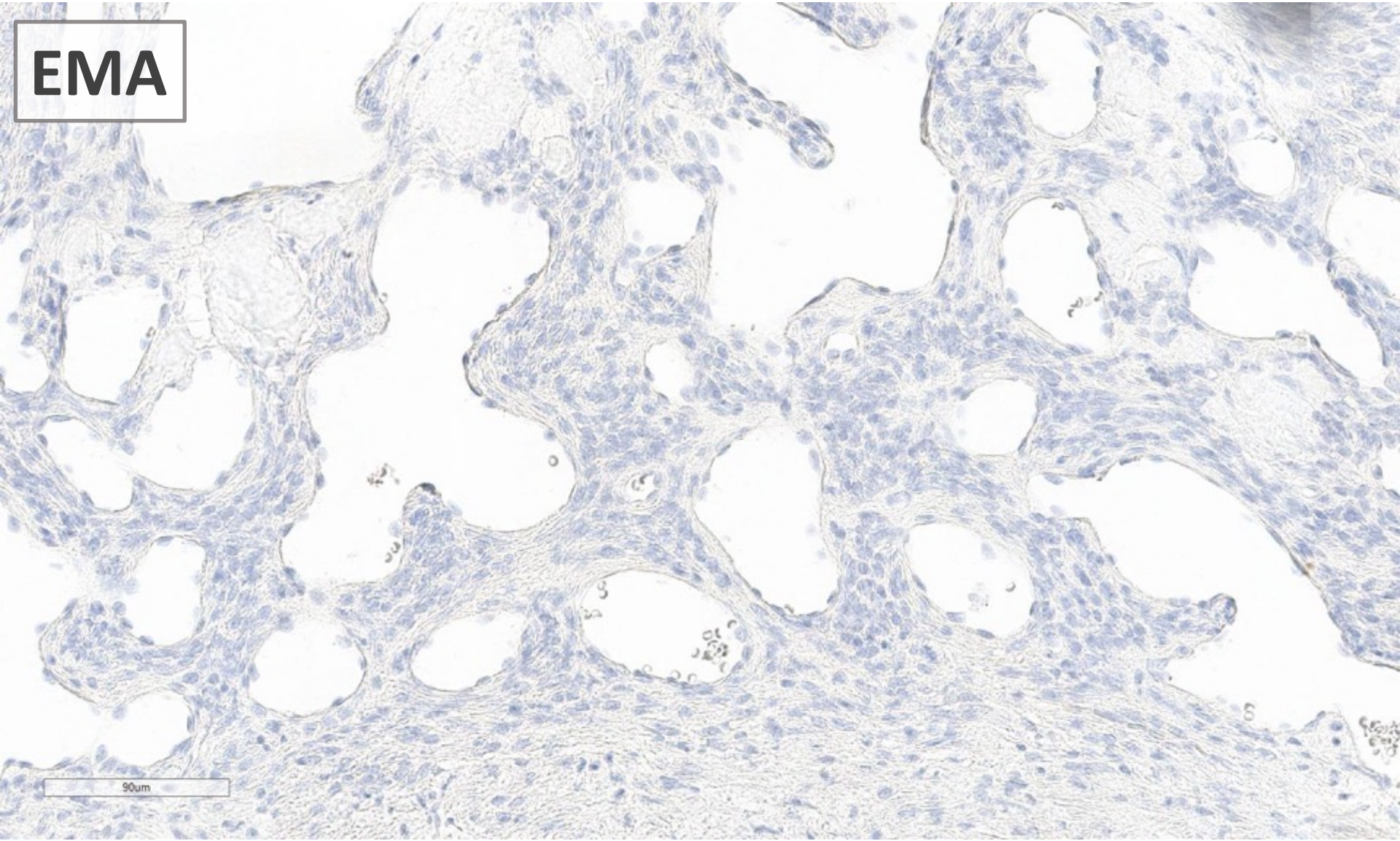
700µm

SMA



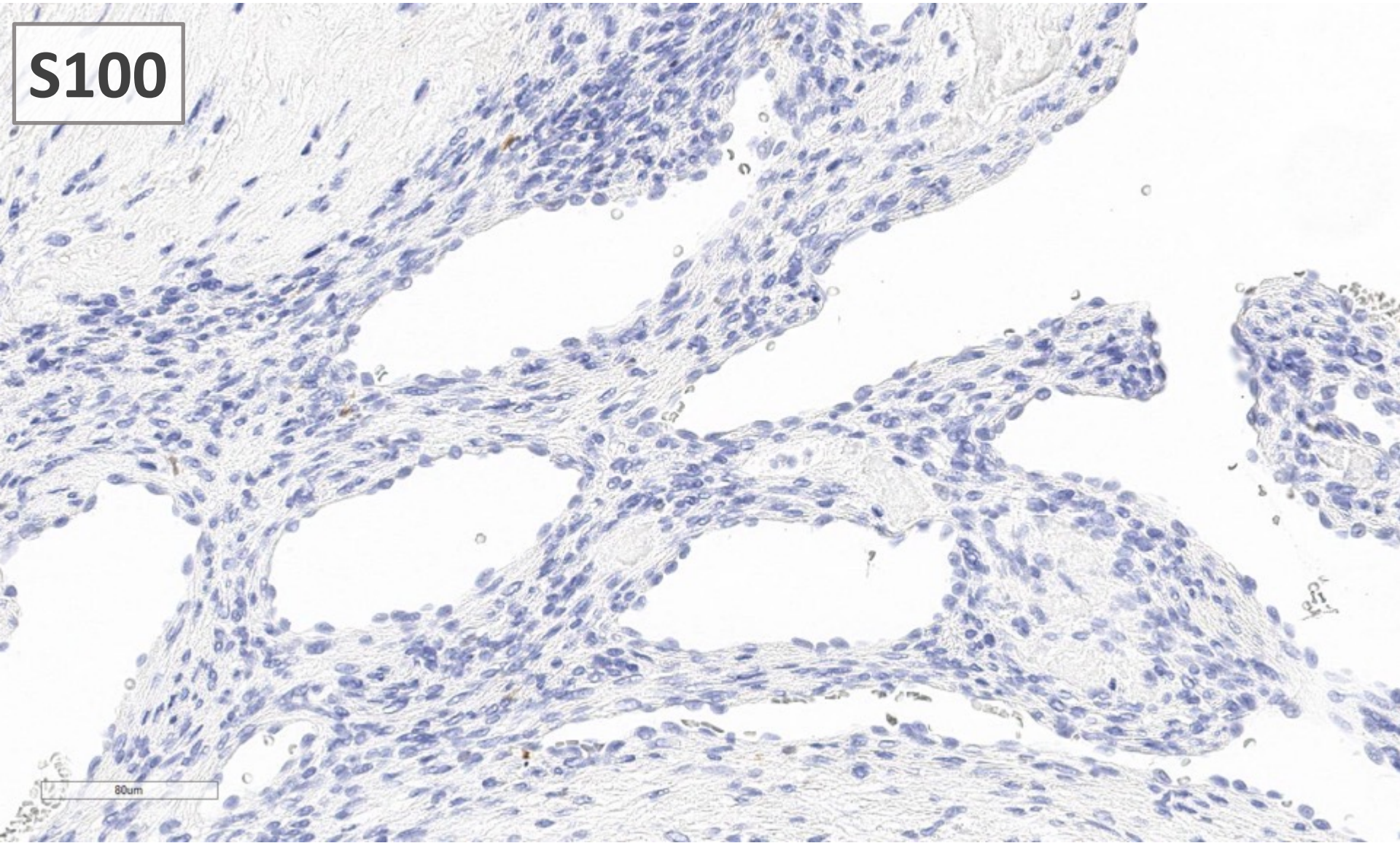
100um

EMA



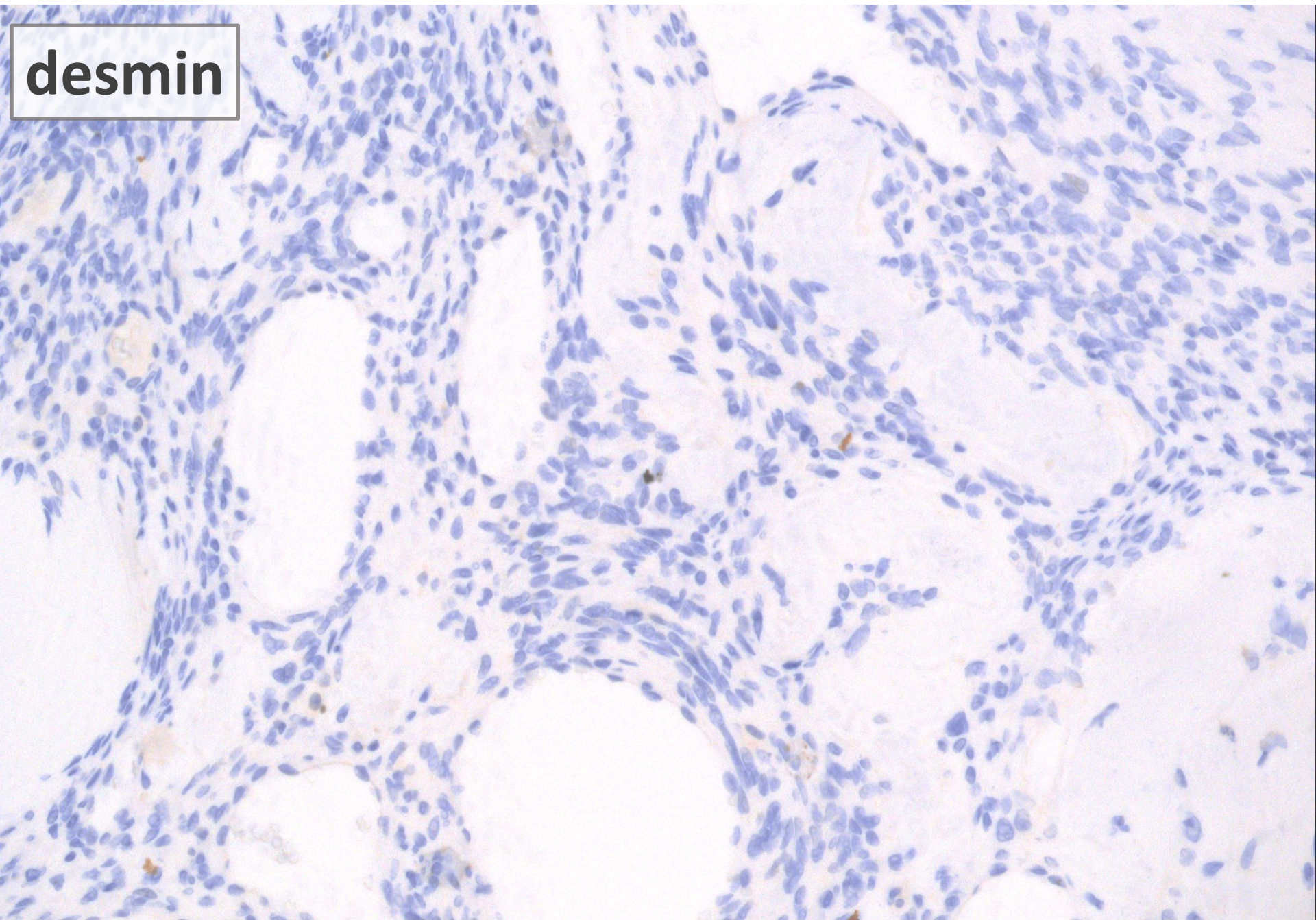
90um

S100



80um

desmin



případ č. 5

Ihc

- **Silná exprese:** SMA
- **Negativní:** EMA, S100, desmin, CD34, STAT6, HMB45



případ č. 5

Diagnóza

Myofibrom



případ č. 5

Myofibrom

- Benigní perivaskulární myoidní neoplazie
- Při narození, v prvních dvou letech života, u dospělých
- **Dermis a hypodermis**, viscerálně nebo intrakraniálně
- **Solitární, myofibromatóza**



případ č. 5

Dif dg

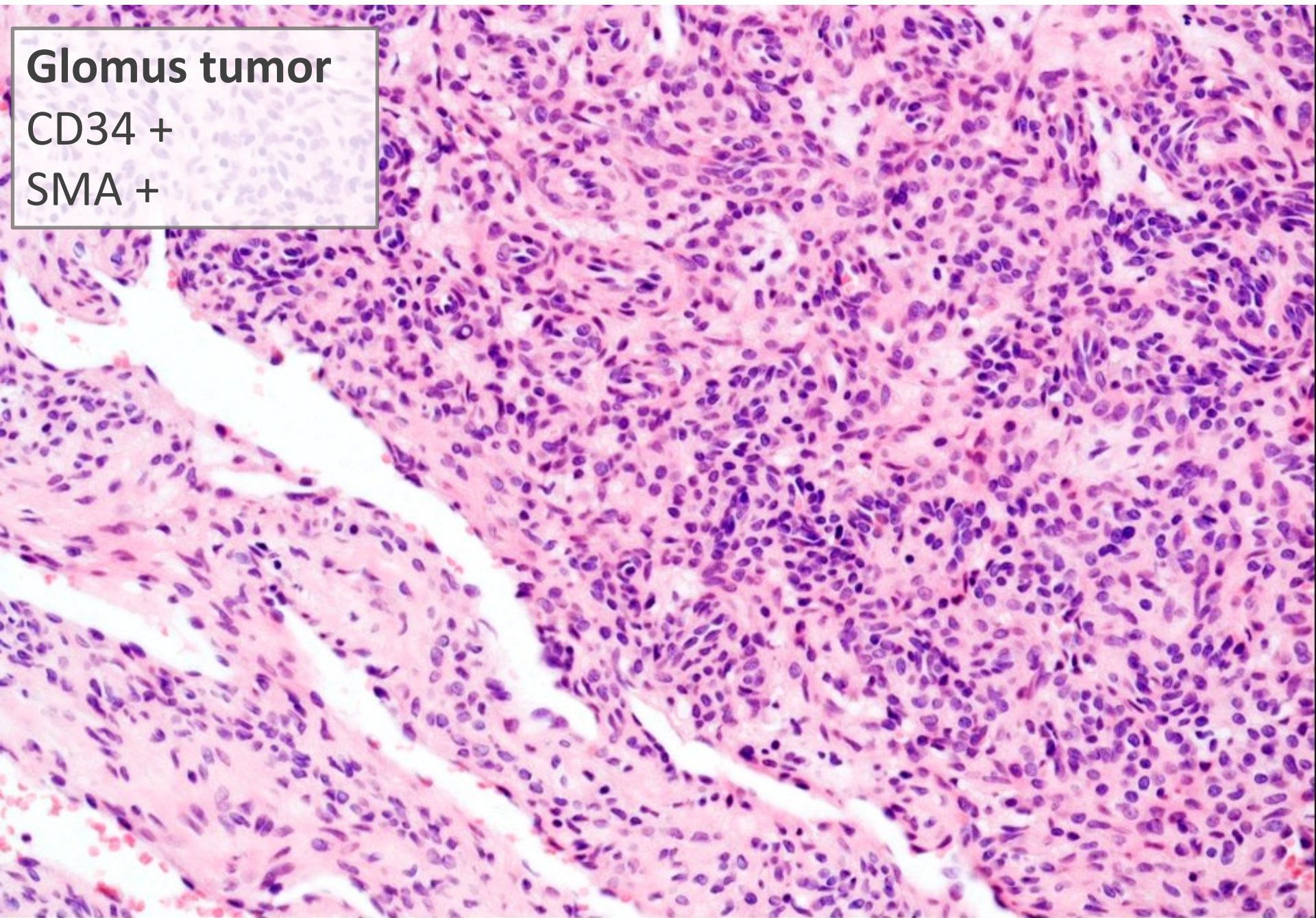
- Glomus tumor
- Angioleiomyom
- PECom
- SFT
- Infantilní fibrosarkom



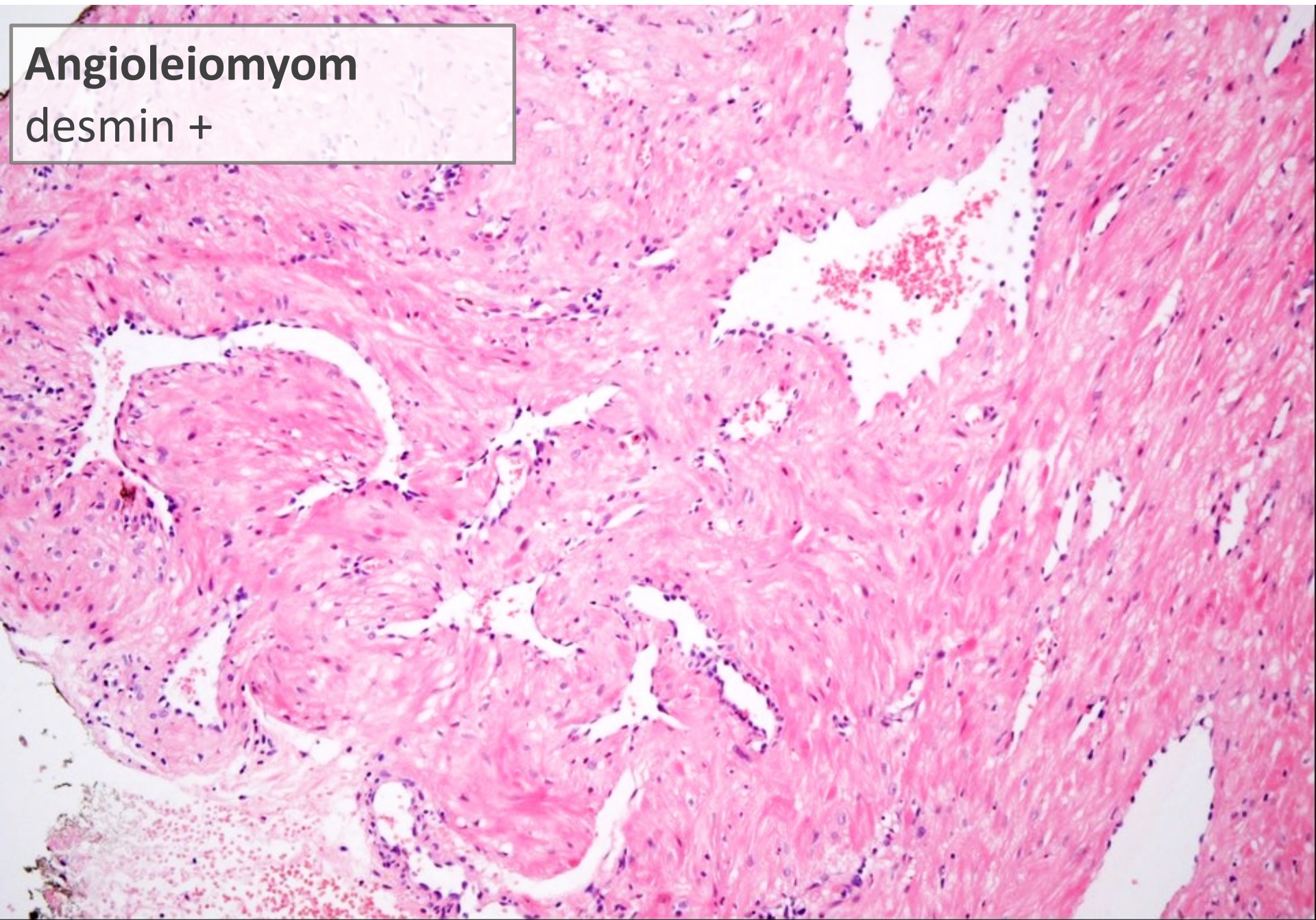
Glomus tumor

CD34 +

SMA +

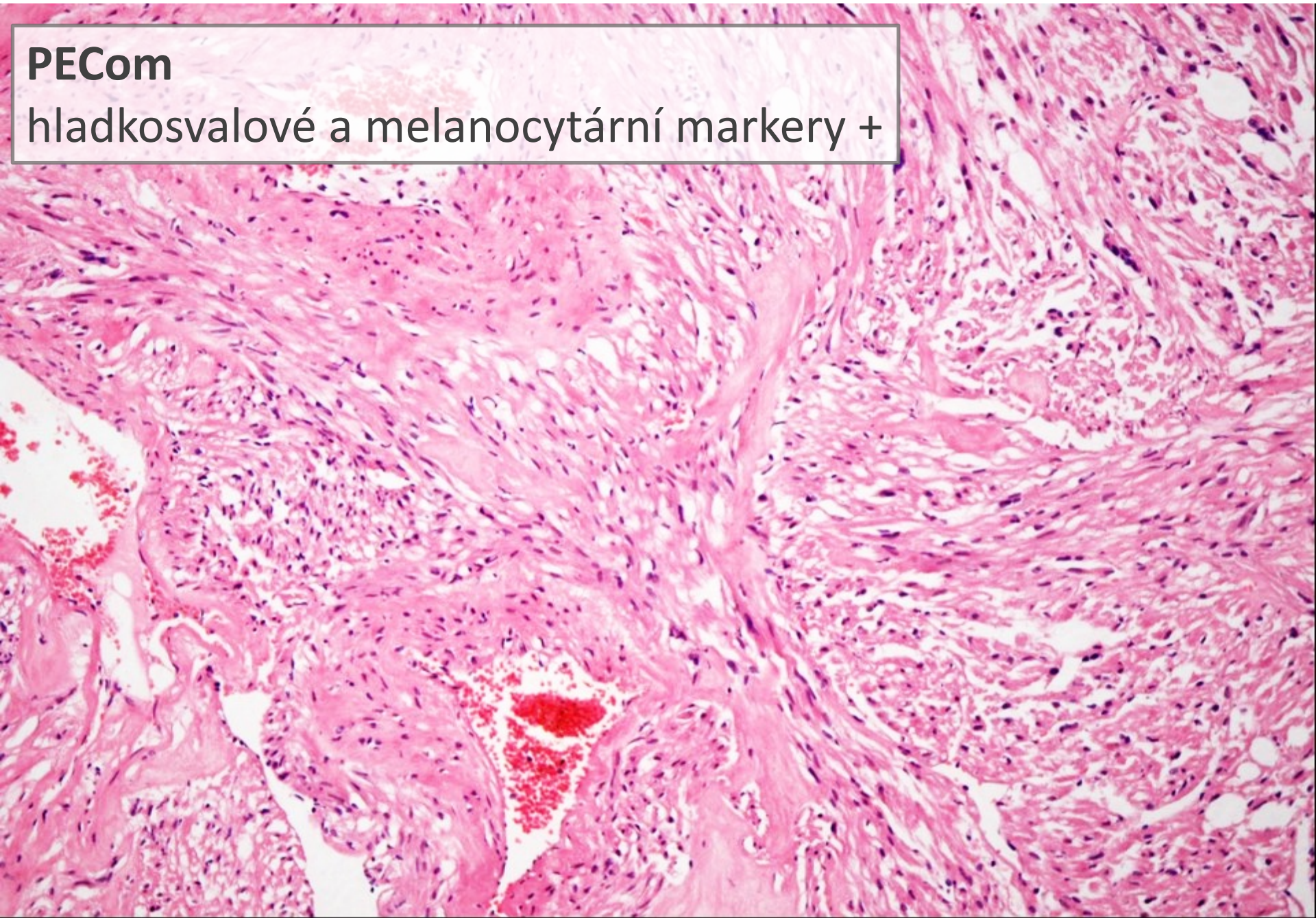


Angioleiomyom
desmin +

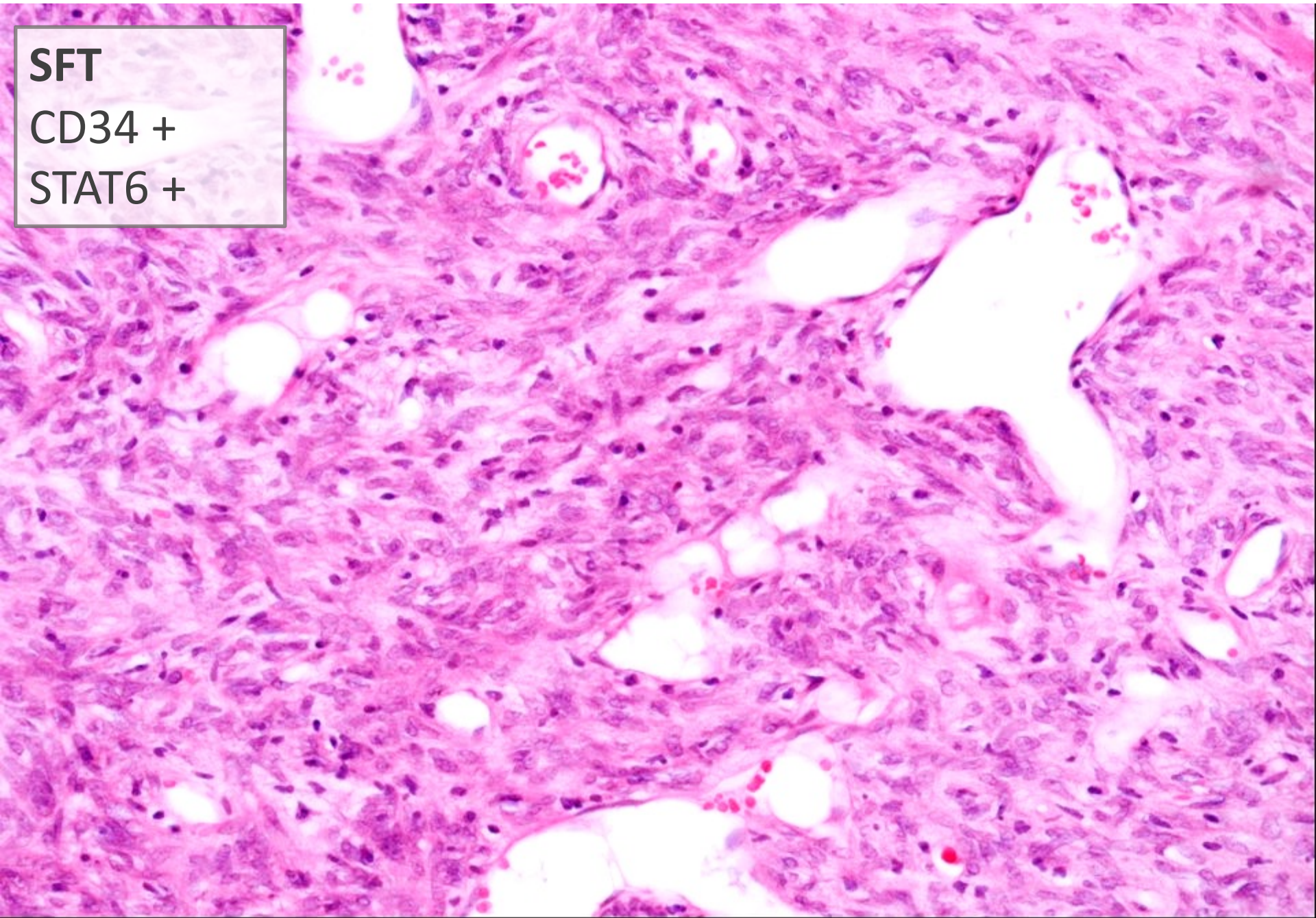


PECom

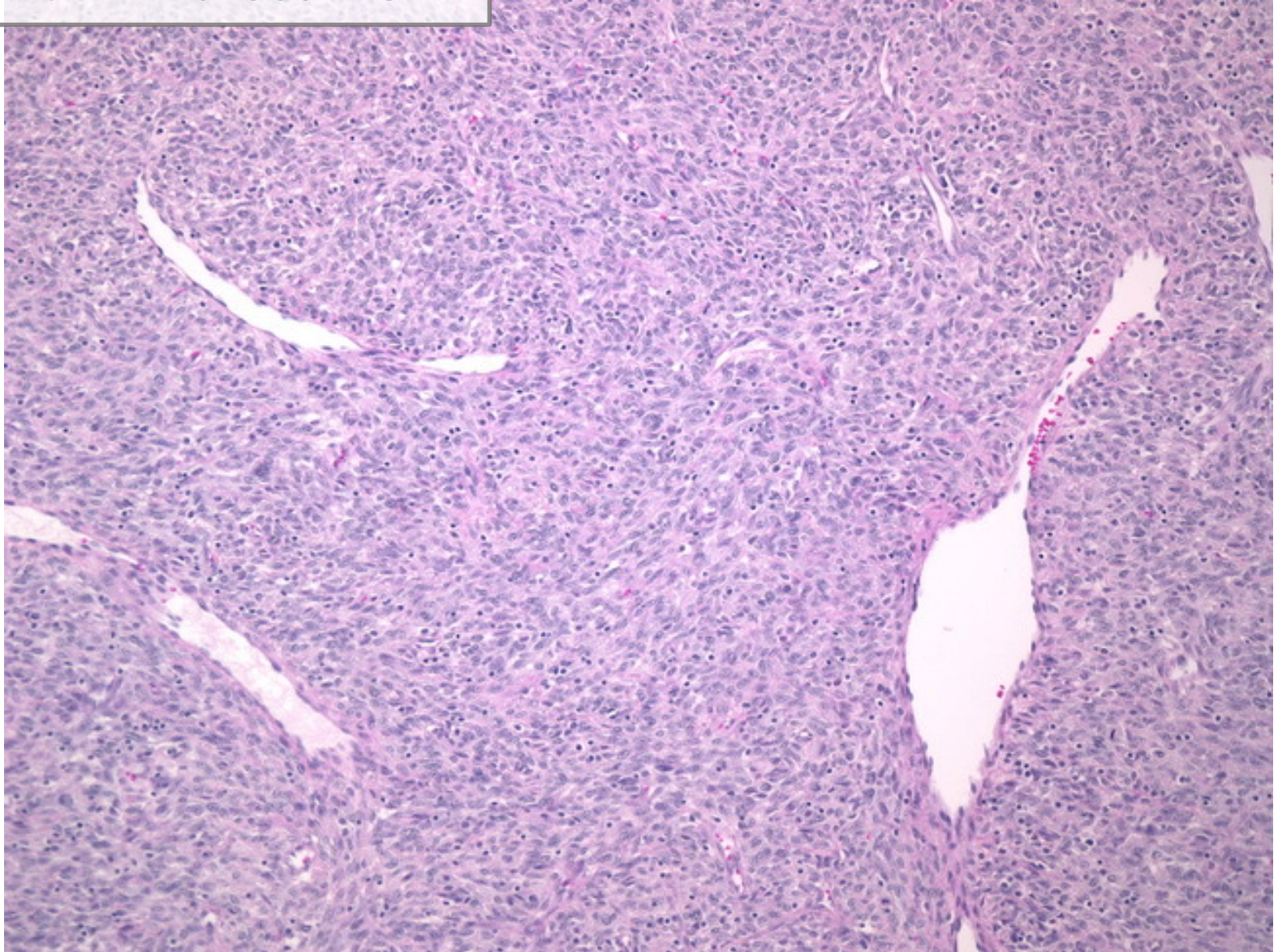
hladkosvalové a melanocytární markery +



SFT
CD34 +
STAT6 +



Infantilní fibrosarkom



<https://www.webpathology.com/image.asp?case=461&n=18>