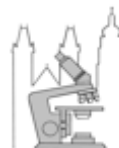

Případ č. 3

Petra Kašparová

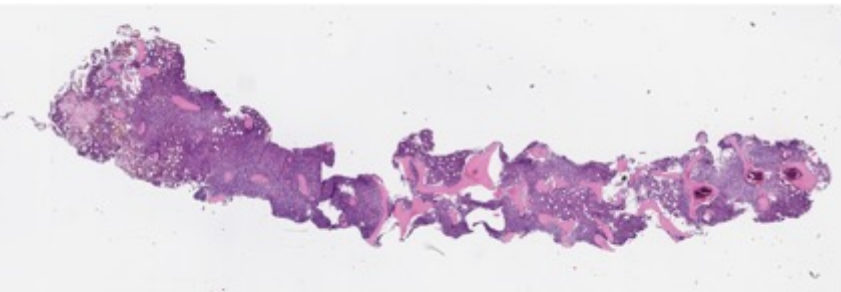


případ č. 3

Klinické údaje & Makropopis

- Ž, 64 let
- krční mízní uzlina

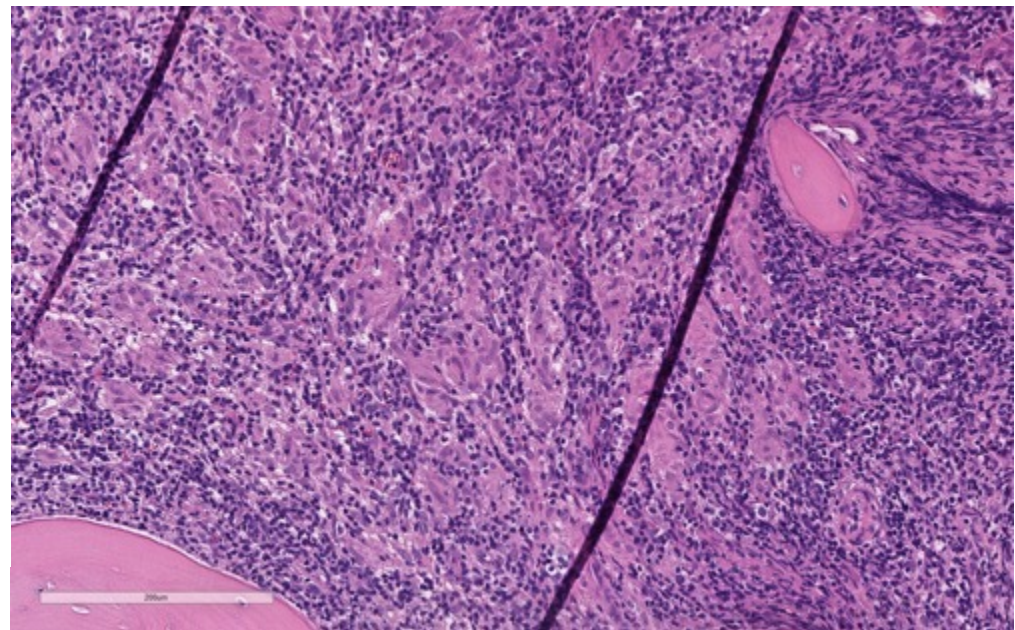
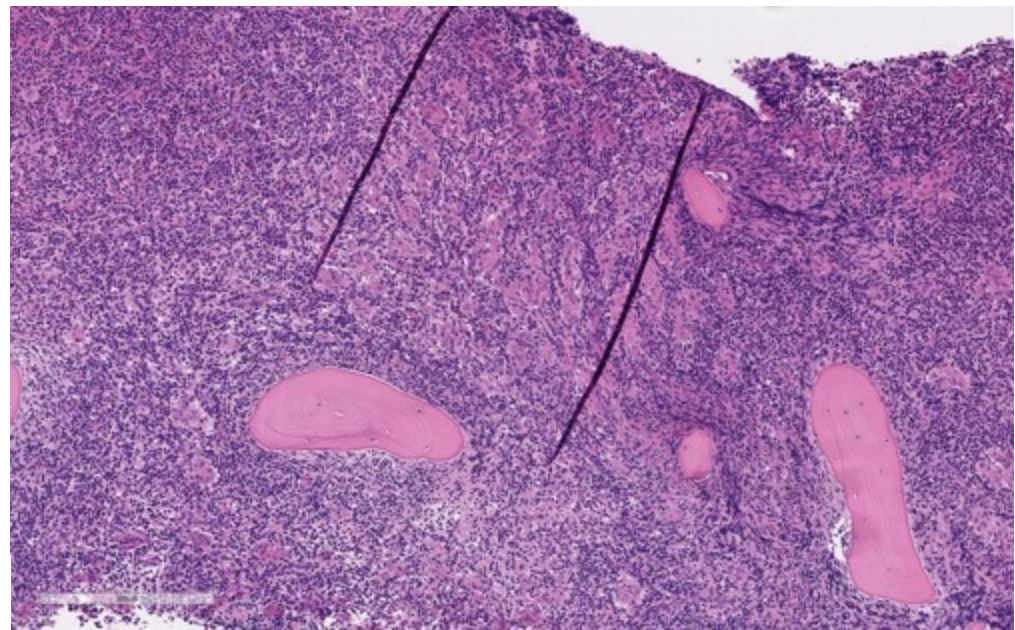




4mm

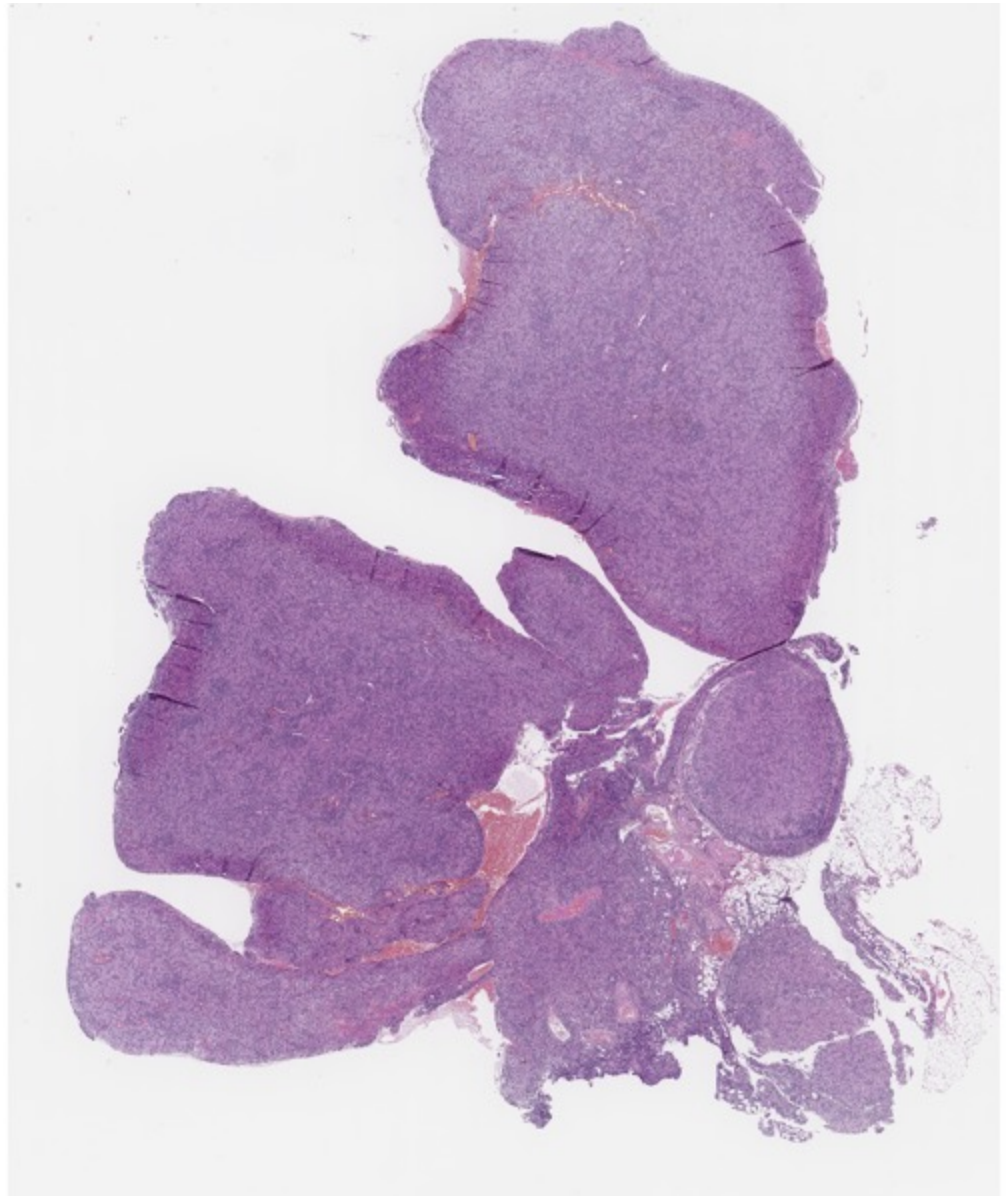


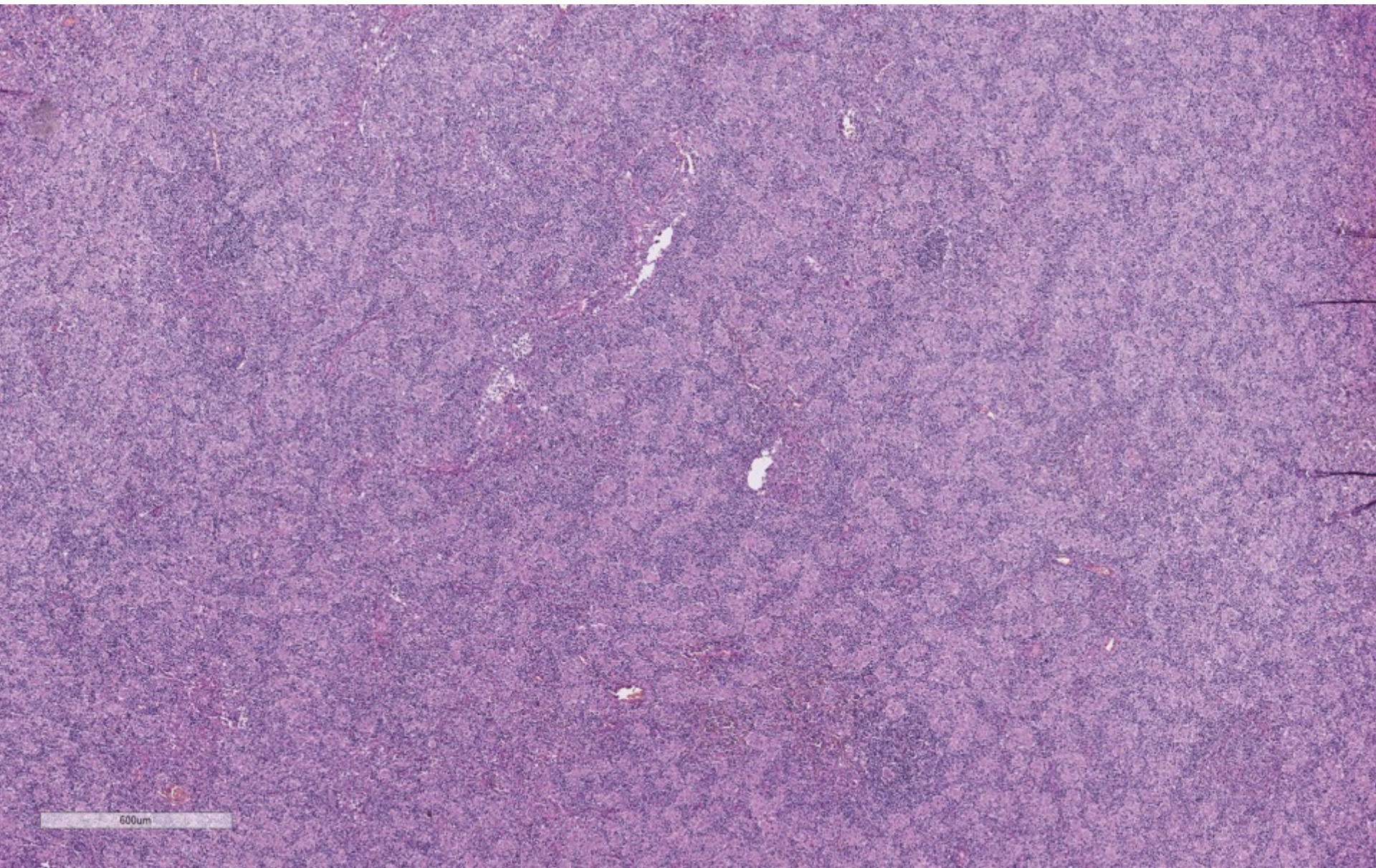
<https://fingerland.smartzoom.com/share/ba10c67b49ad06aca03b0>



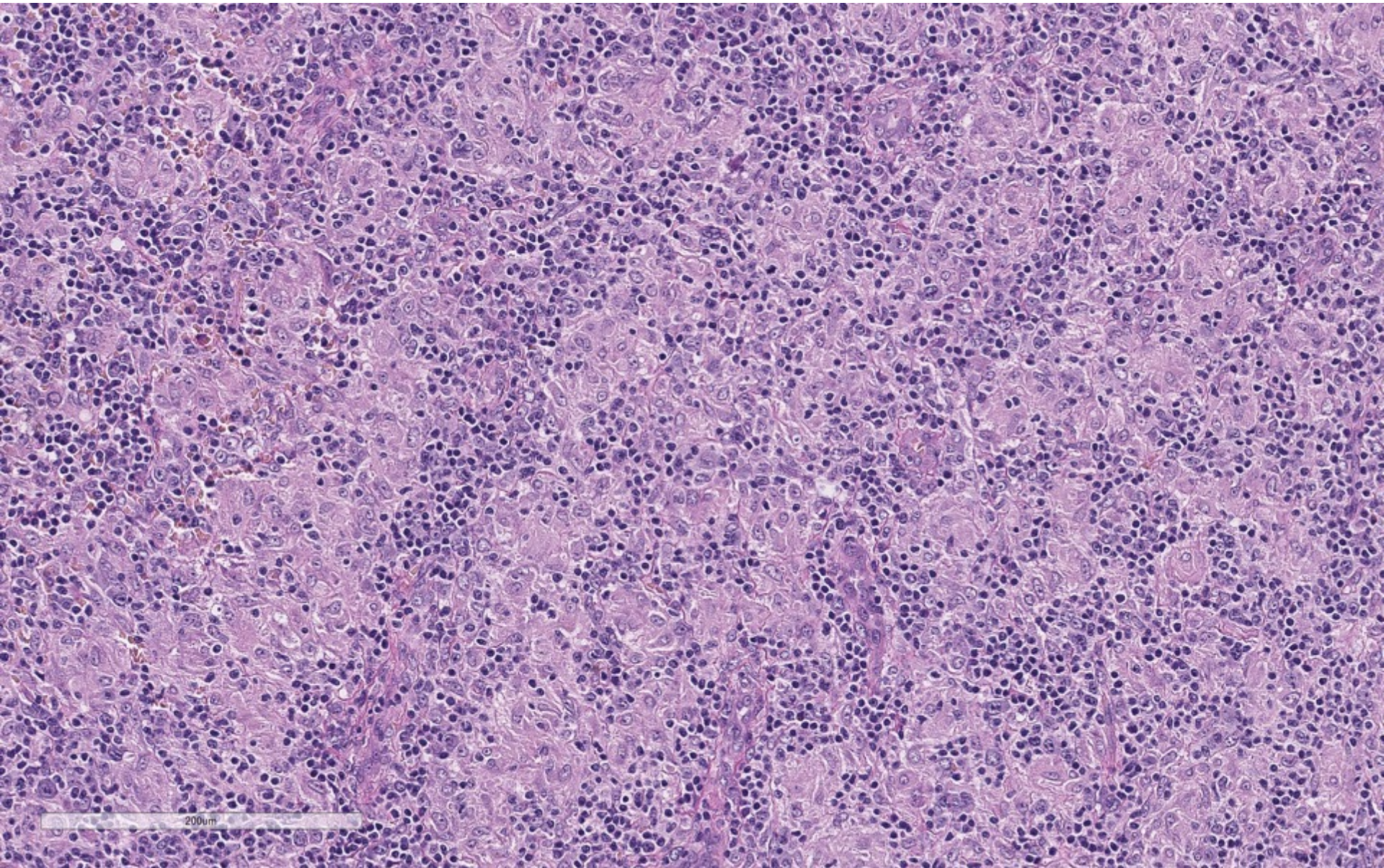


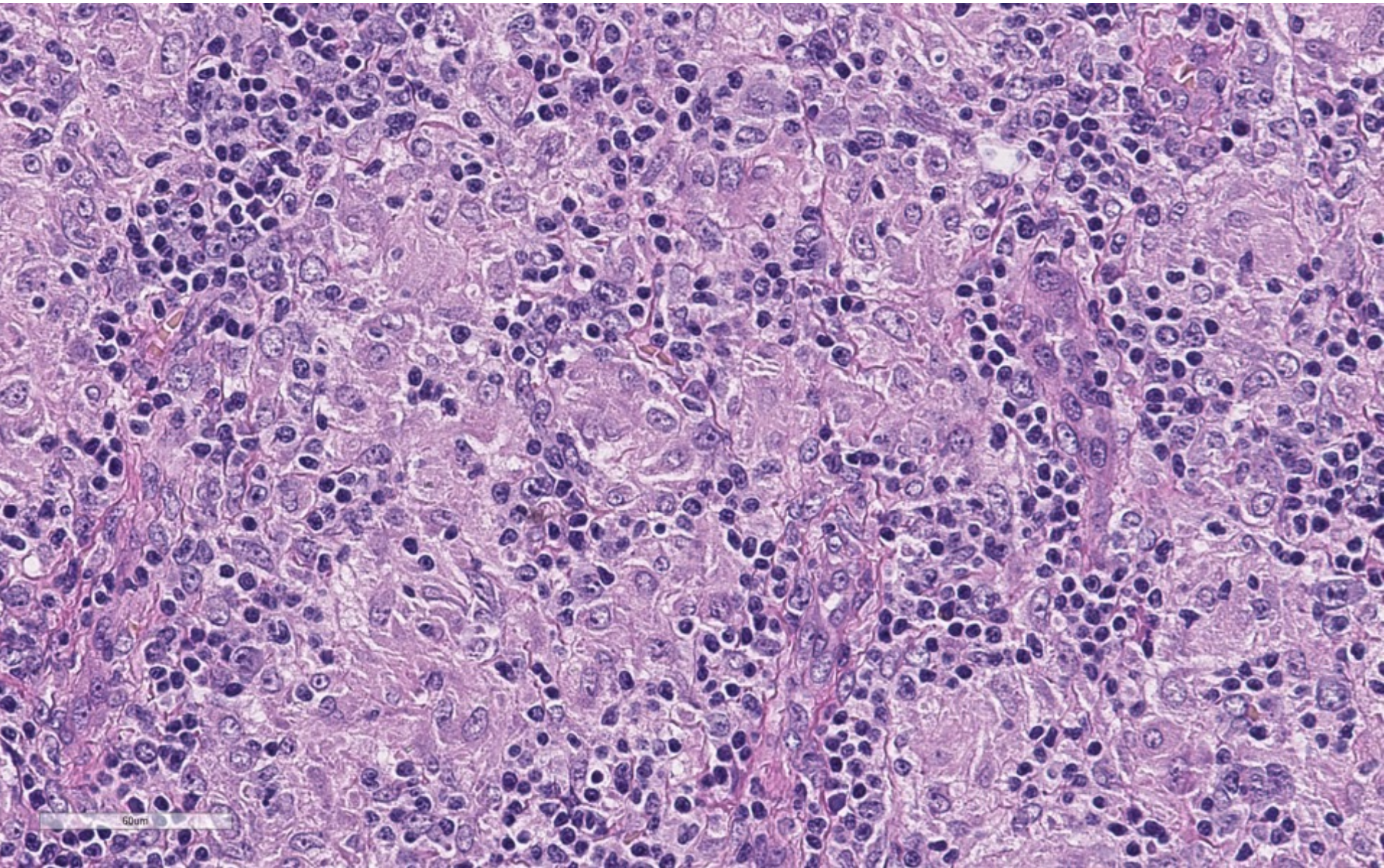
<https://fingerland.smartzoom.com/share/f0f2eb91bfeb199032766e>





500um

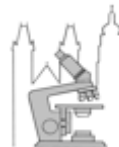



případ č. 3

Ihc – lymfoidní elementy

- pozitivní:
 - **CD3**
 - CD2, CD5, CD7
 - granzyme B, TIA
 - GATA3, CD8, CD183, CCR4
- negativní:
 - CD4, PD1, ICOS



případ č. 3

Diagnóza

**T-NHL, PTCL, NOS – GATA3,
morfologicky lymfoepiteloidního typu
(Lennertův lymfom)**



případ č. 3

Diskuze

- problematika T-NHL obtížná
- překryv / přechod:
 - (auto)imunitní onemocnění
 - virová onemocnění...



případ č. 3

Dif Dg

- granulomatózní lymfadenopatie

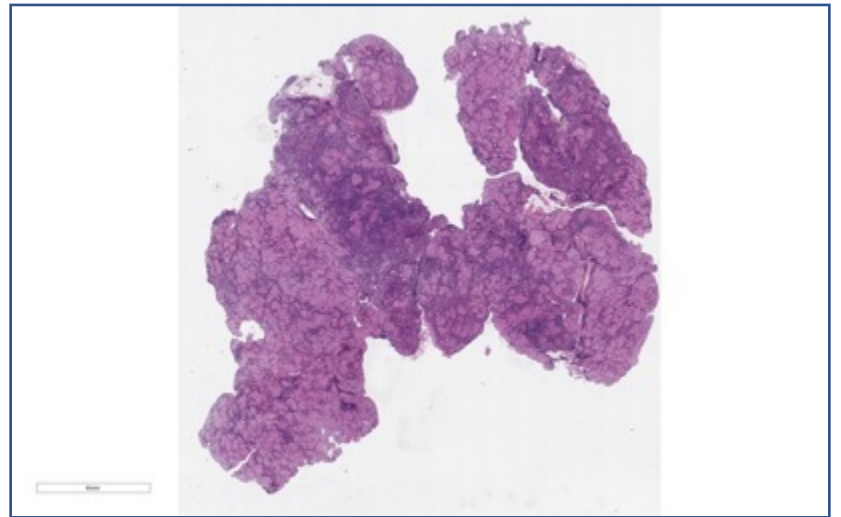


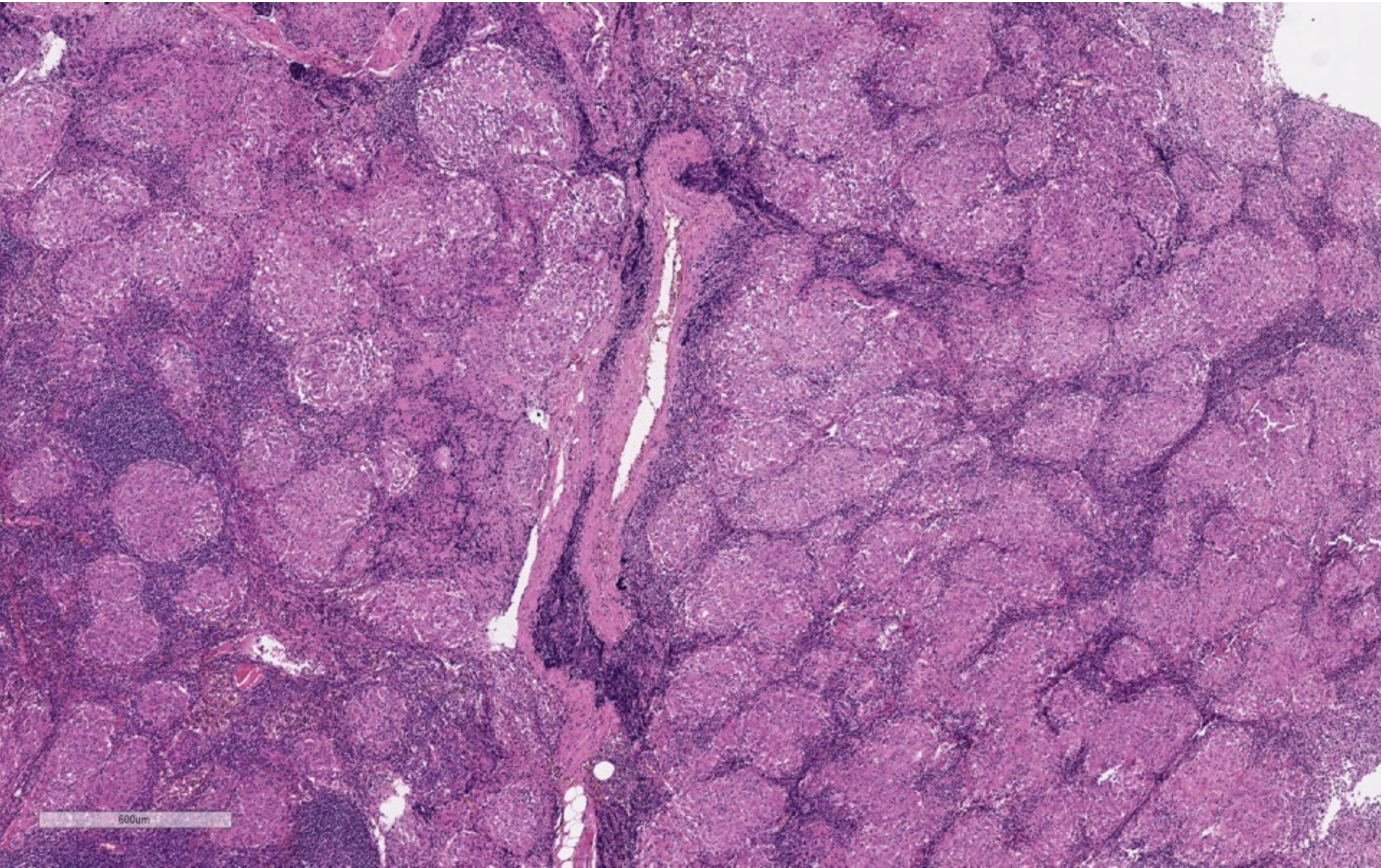
granulomatózní LAP_01

muž, 48 let, mediastinum

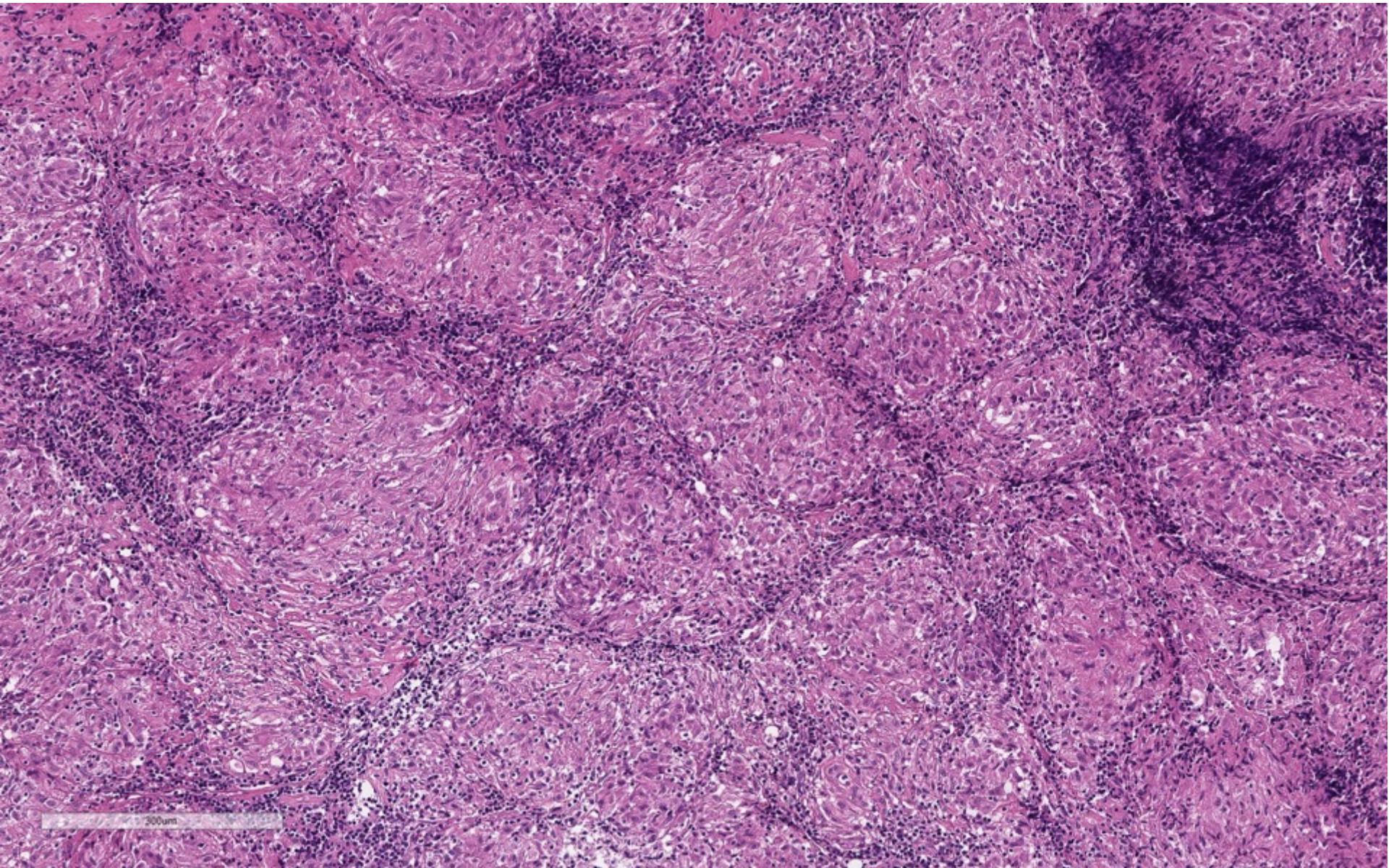



<https://fingerland.smartzoom.com/share/231a6828321c919876e9d>





600um



A histological micrograph showing multiple non-necrotizing granulomas. Each granuloma is a well-circumscribed collection of epithelioid histiocytes, some multinucleated Langhans-type giant cells, and a sparse infiltrate of lymphocytes. The granulomas are separated by thin layers of fibrous tissue. The overall appearance is characteristic of sarcoidosis.

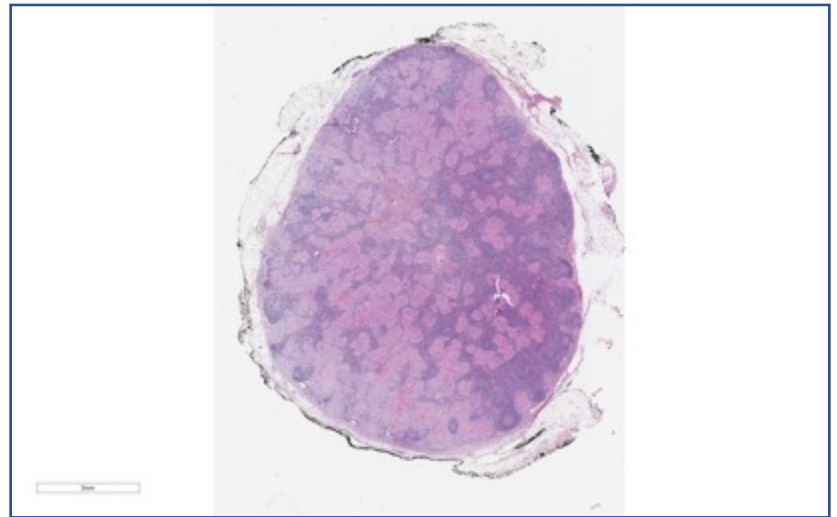
splývající granulomy bez
nekrotizace – sarkoidóza

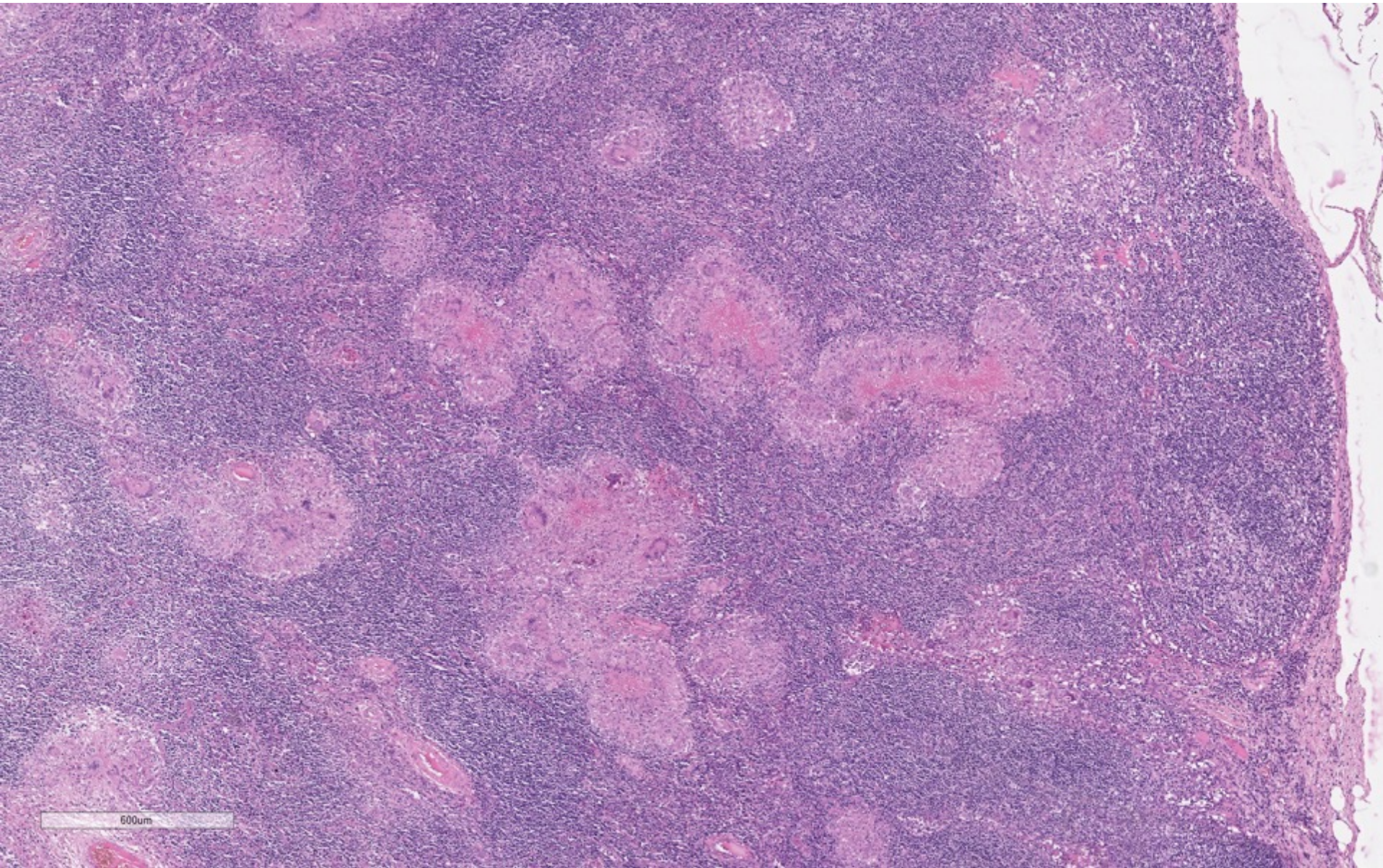
granulomatózní LAP_02

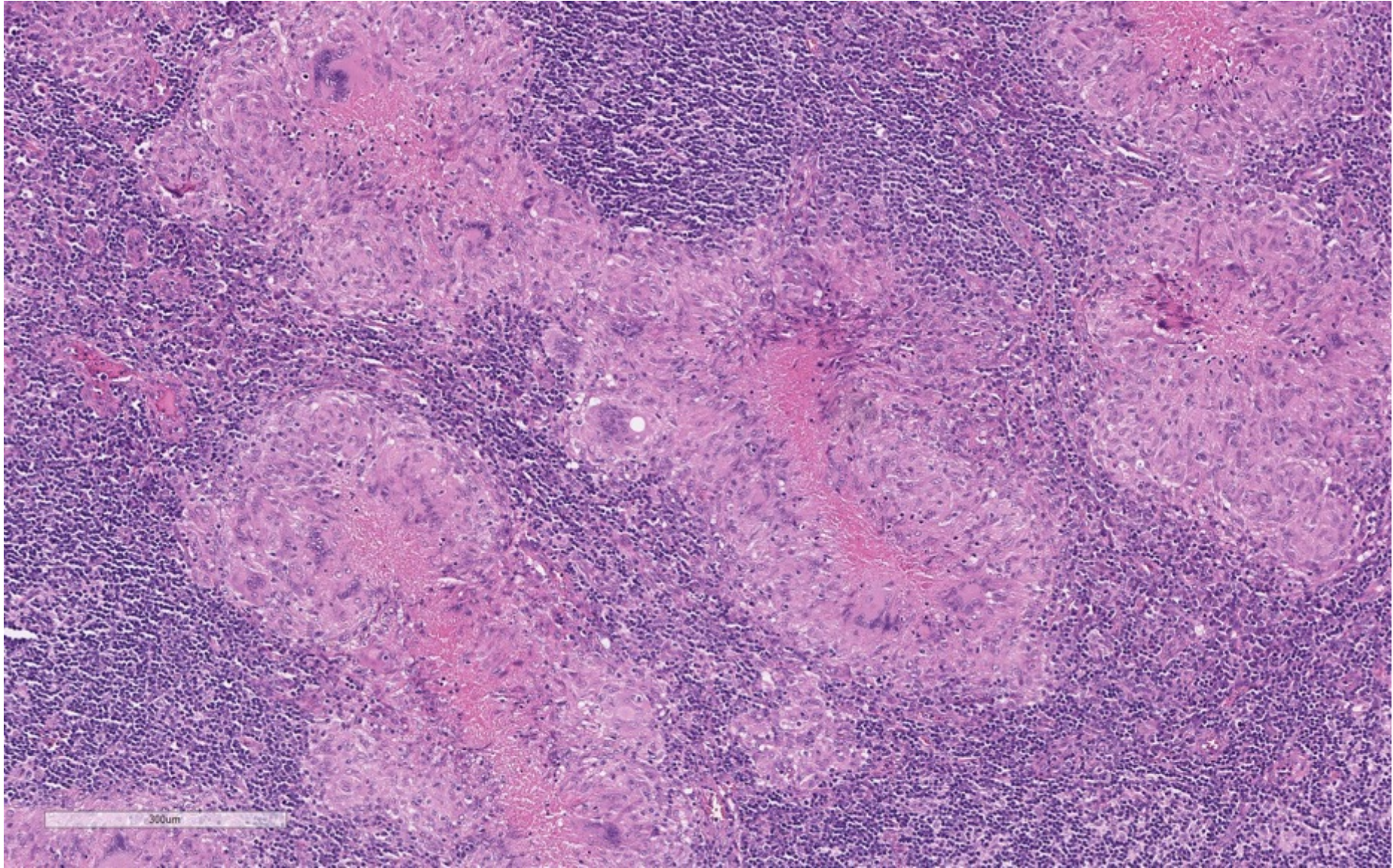
muž, 23 let, nadklíček



<https://fingerland.smartzoom.com/share/f55a94a3396aa4440a491c>









granulomy s kaseifikací – TBC

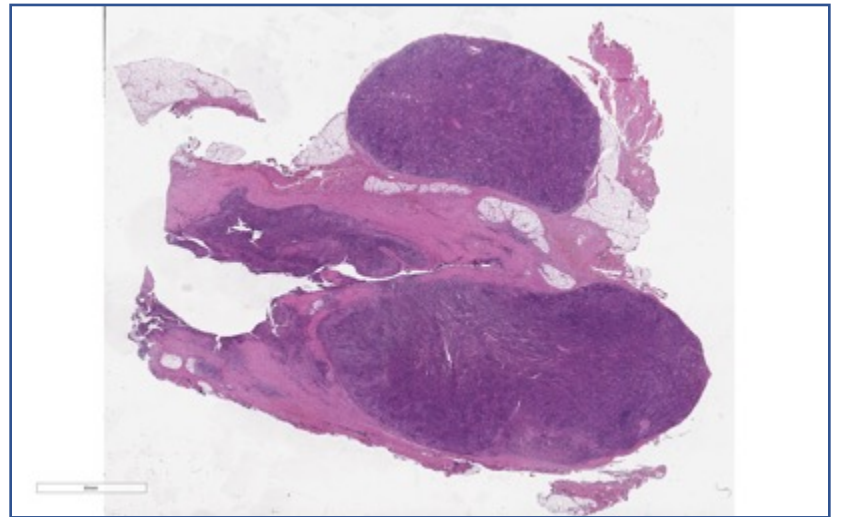
300um

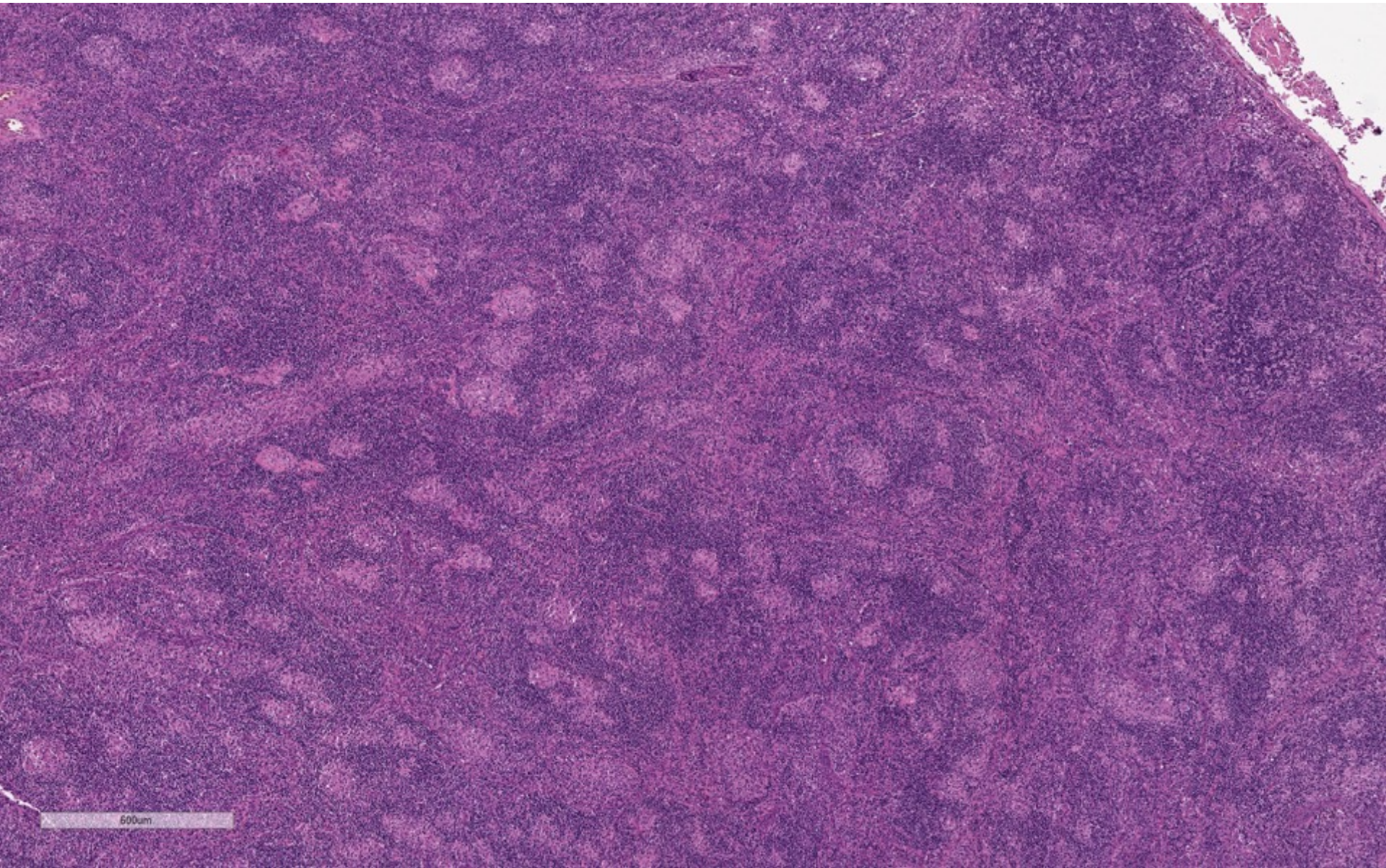
granulomatózní LAP_03

žena, 3 měsíce, axila, BCG vakcinace

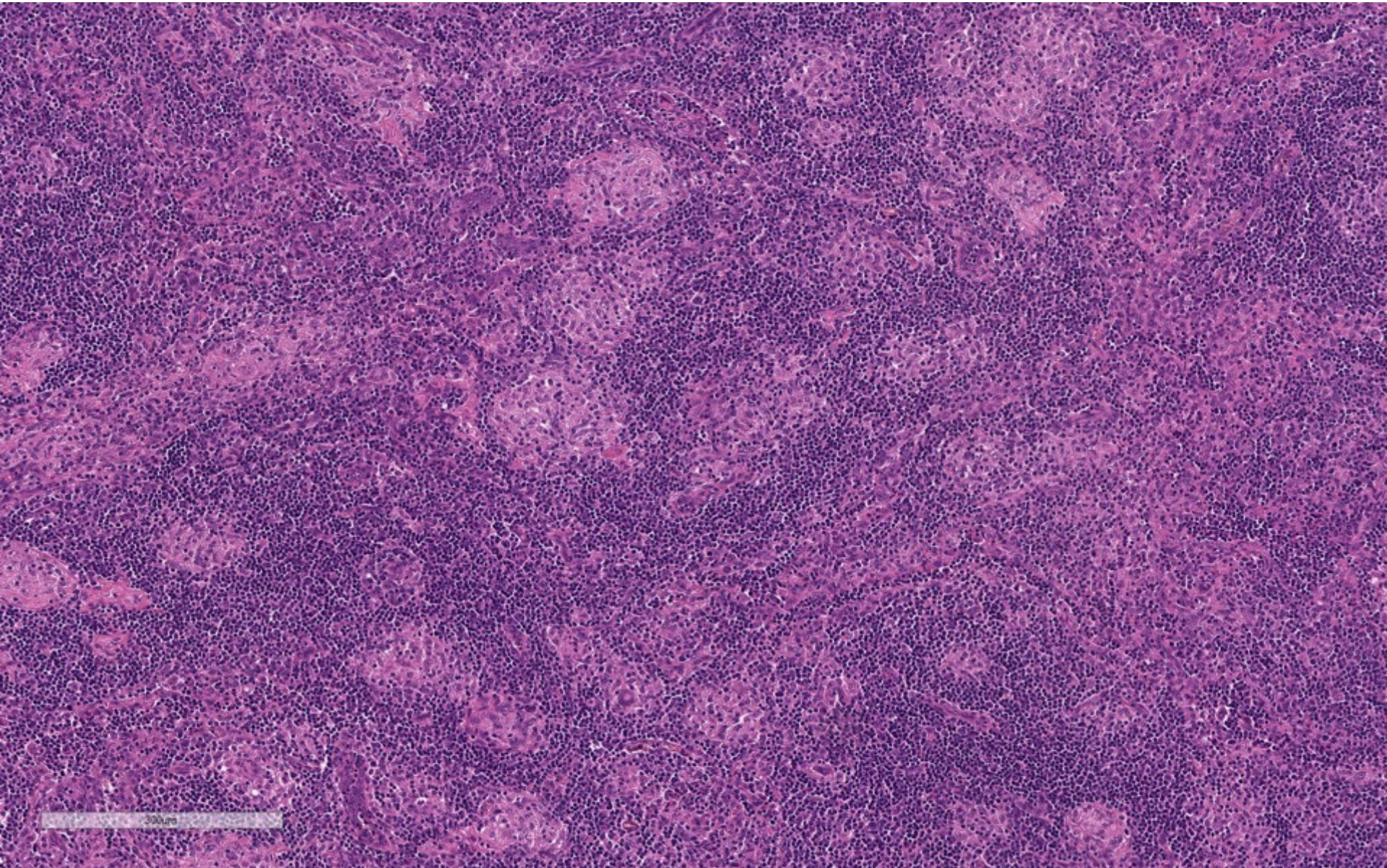



<https://fingerland.smartzoom.com/share/7727a0cce56f4685636a0c>





600um





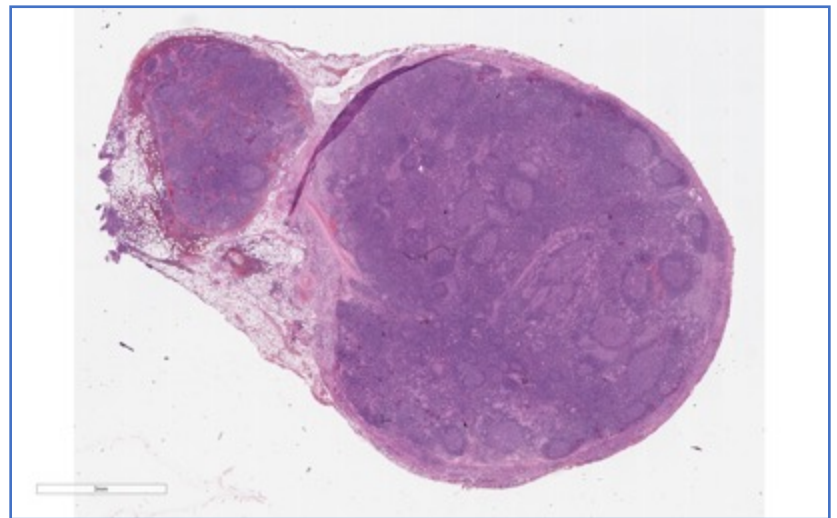
jednotlivé granulomy bez
nekrotizace – „miliární“ BCGitida

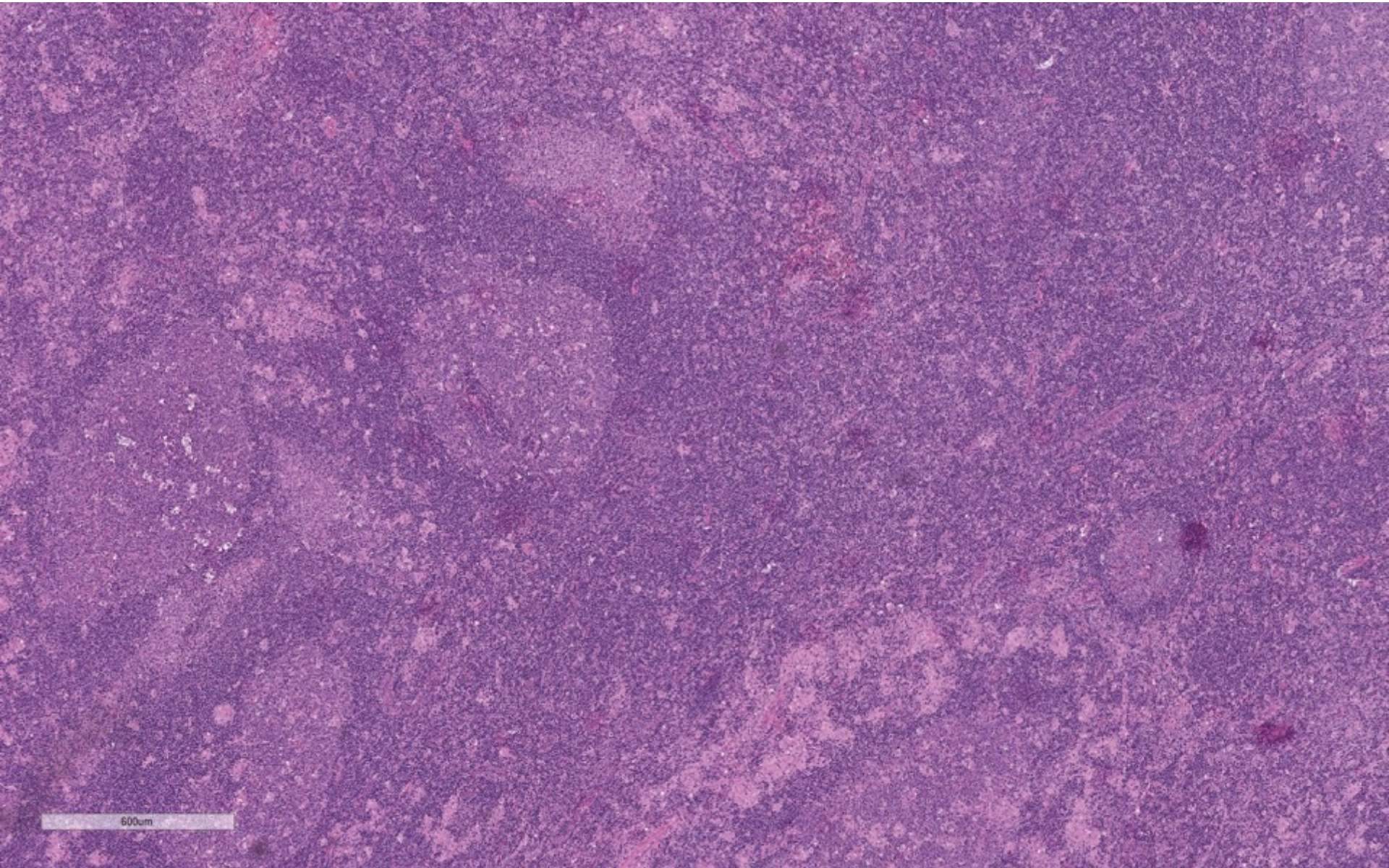
granulomatózní LAP_04

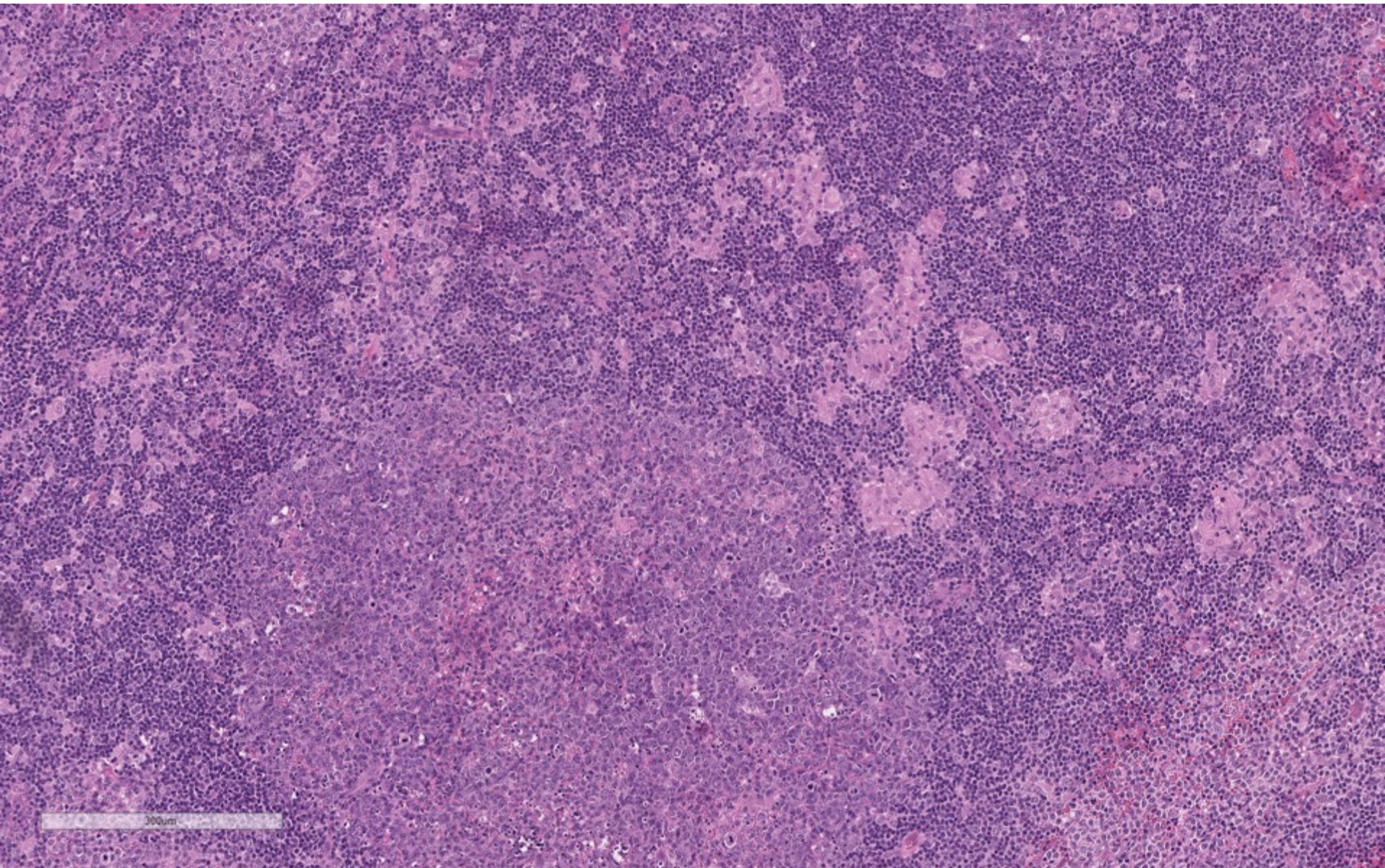
muž, 34, nadklíček




<https://fingerland.smartzoom.com/share/5f93f55f5ae4bed1c27ab3>









jednotlivé histiocyty až drobné granulomy, normální architektika – toxoplazmóza

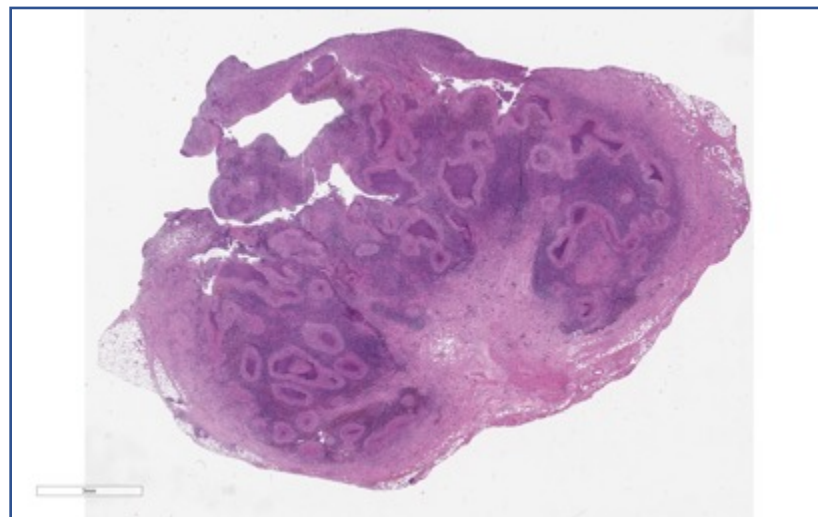
300um

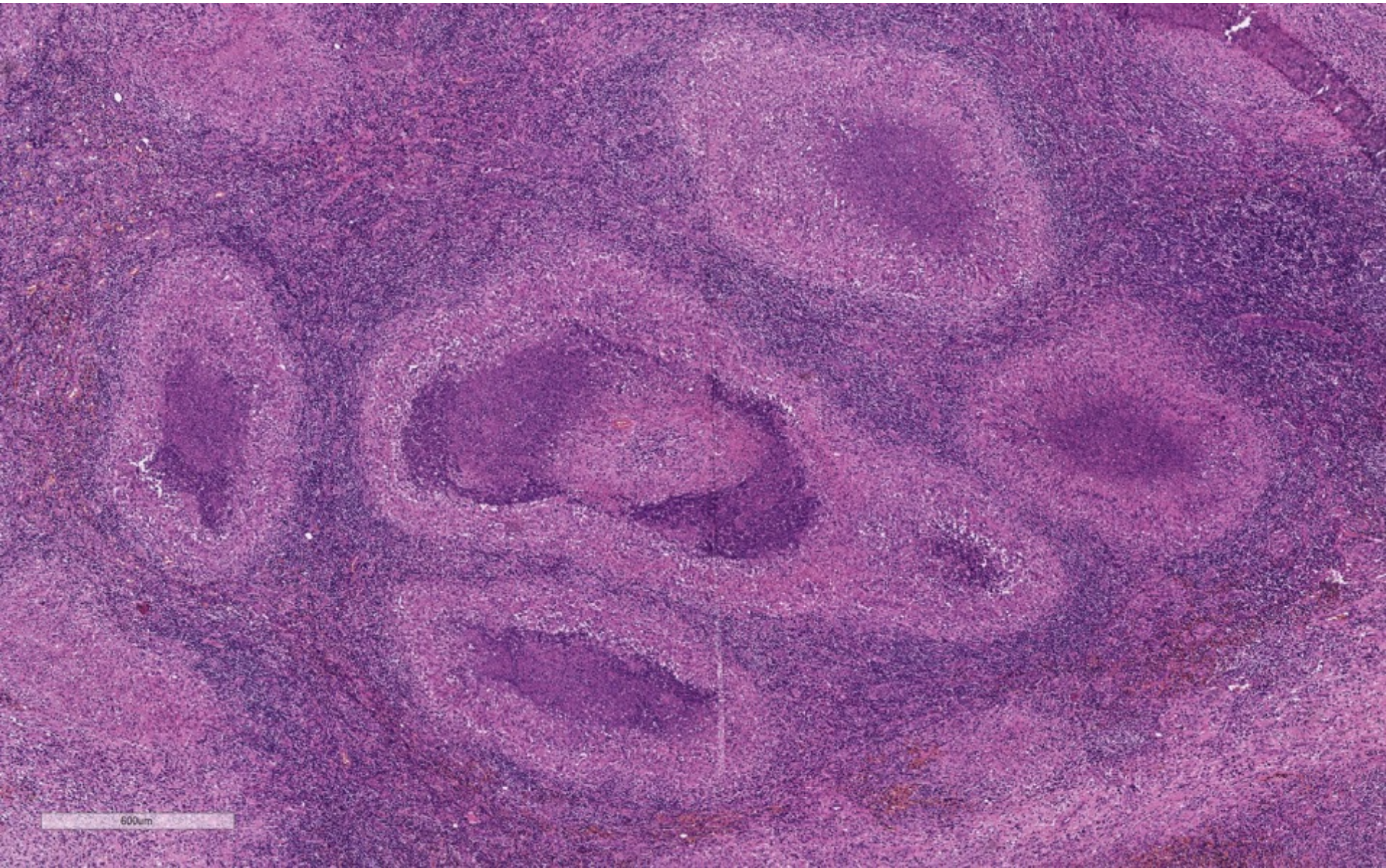
granulomatózní LAP_05

žena, 41, tříslo

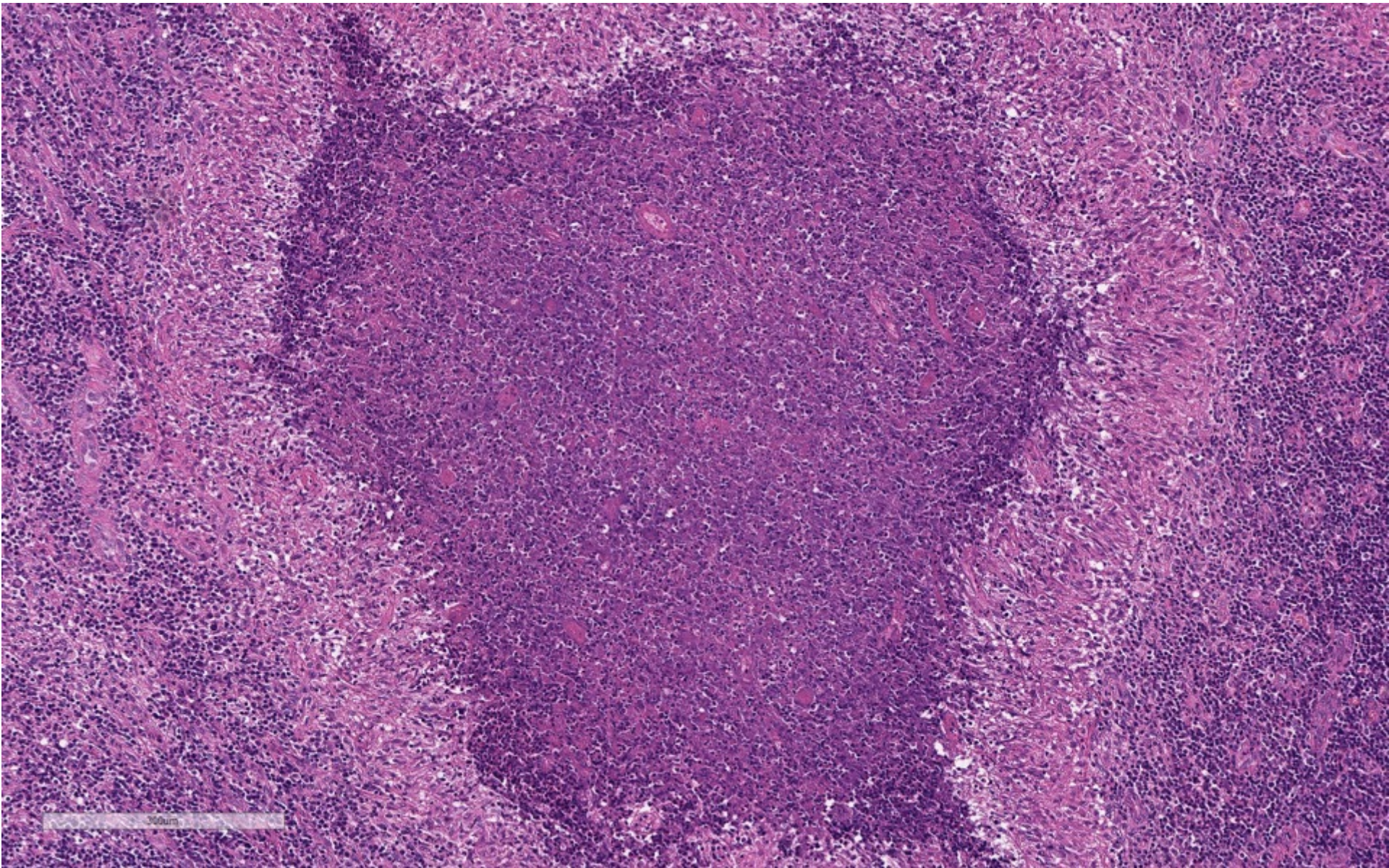


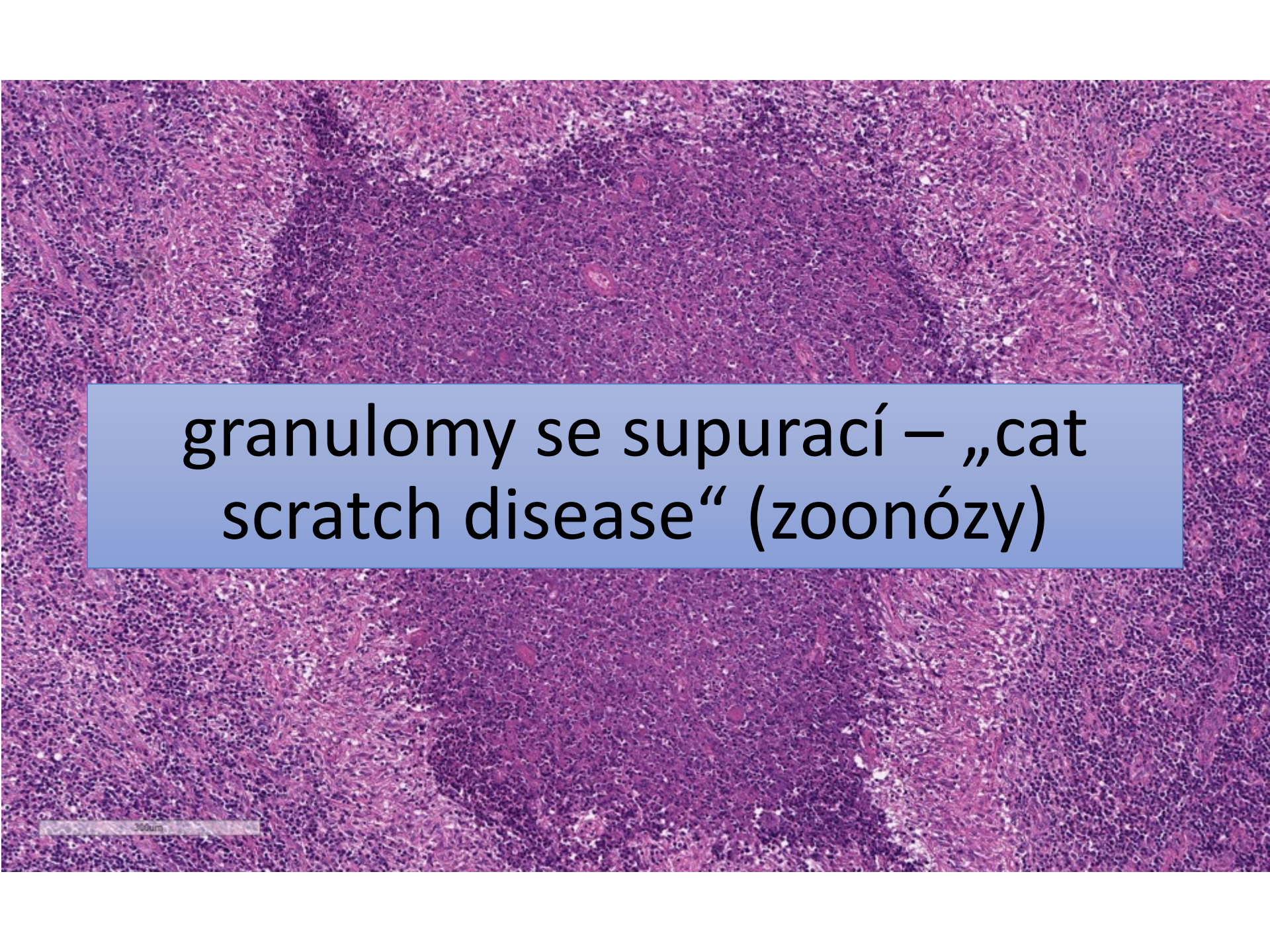
<https://fingerland.smartzoom.com/share/49a3ec385c395e21e185a>





600µm





granulomy se supurací – „cat scratch disease“ (zoonózy)

300um