22. Seminář mladých patologů

22. – 23. 10. 2021

Litomyšl

Případ č. 2

Jan Laco

případ č. 2
Klinická data

- žena, 24 let
- subj.: bolesti v podbřišku + metroragie (3/2019)
- UZ + CT:
  - solidně cystická rezistence v MP 135 x 100 mm, NE ascites
  - v. s. levá adnexa, v. s. mucinózní karcinom
- ↑ CA125; HE4 norma
- AT l. sin. + frozen section (adultní GCT ⇒ konzultace)
- chemoterapie + stagingová chirurgie (NED) … FIGO IA
- 9/2021 … NED

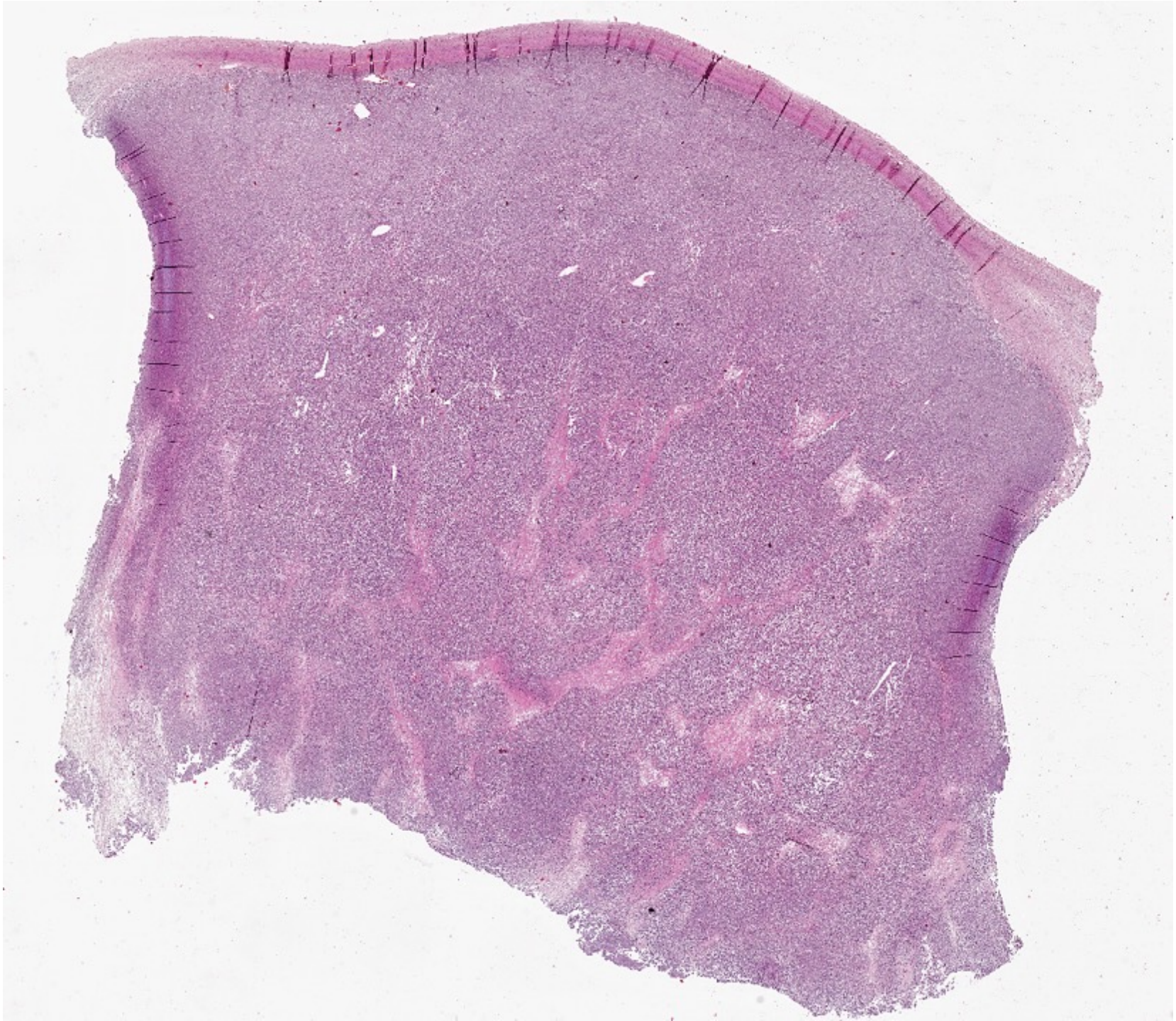

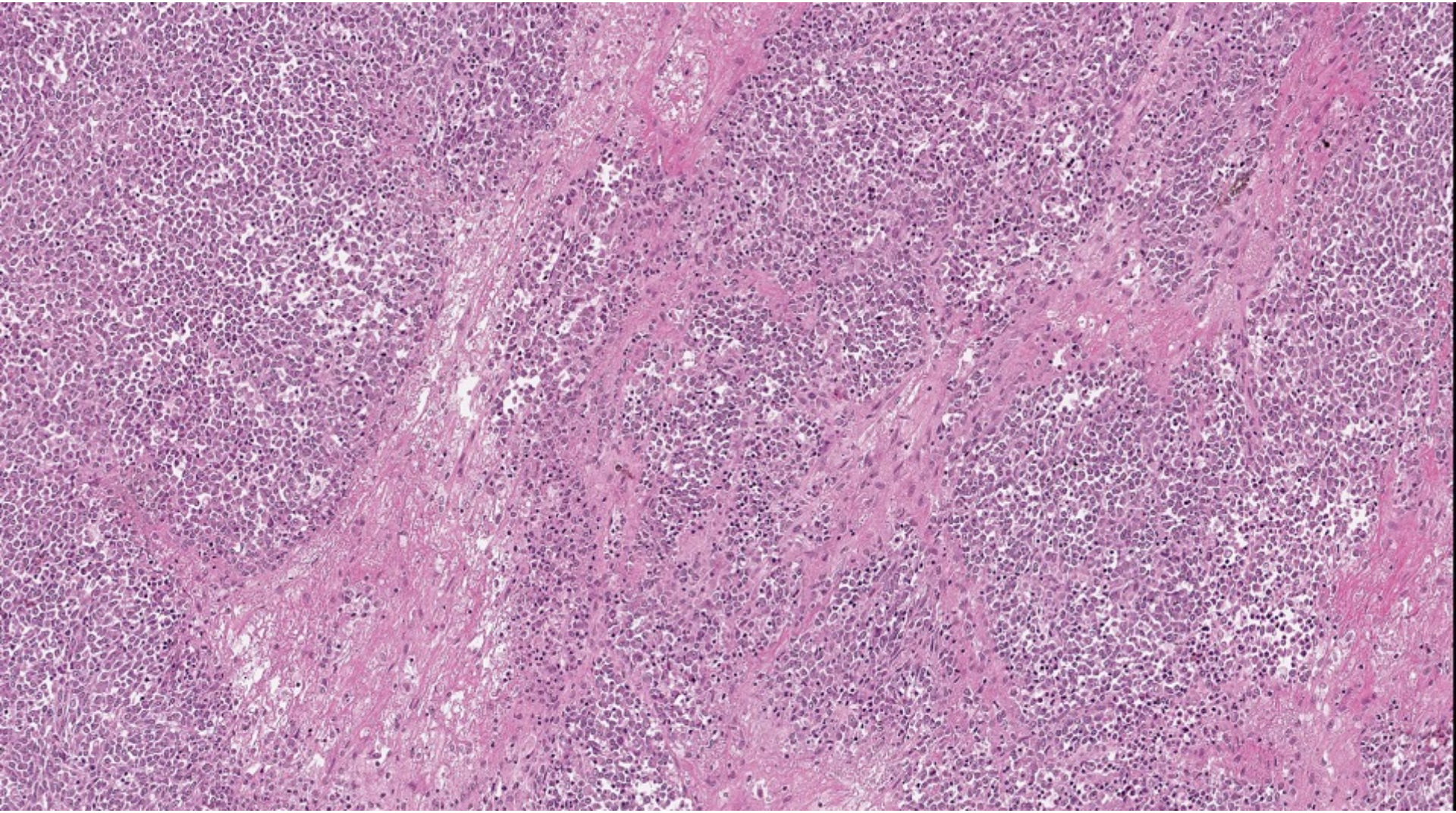

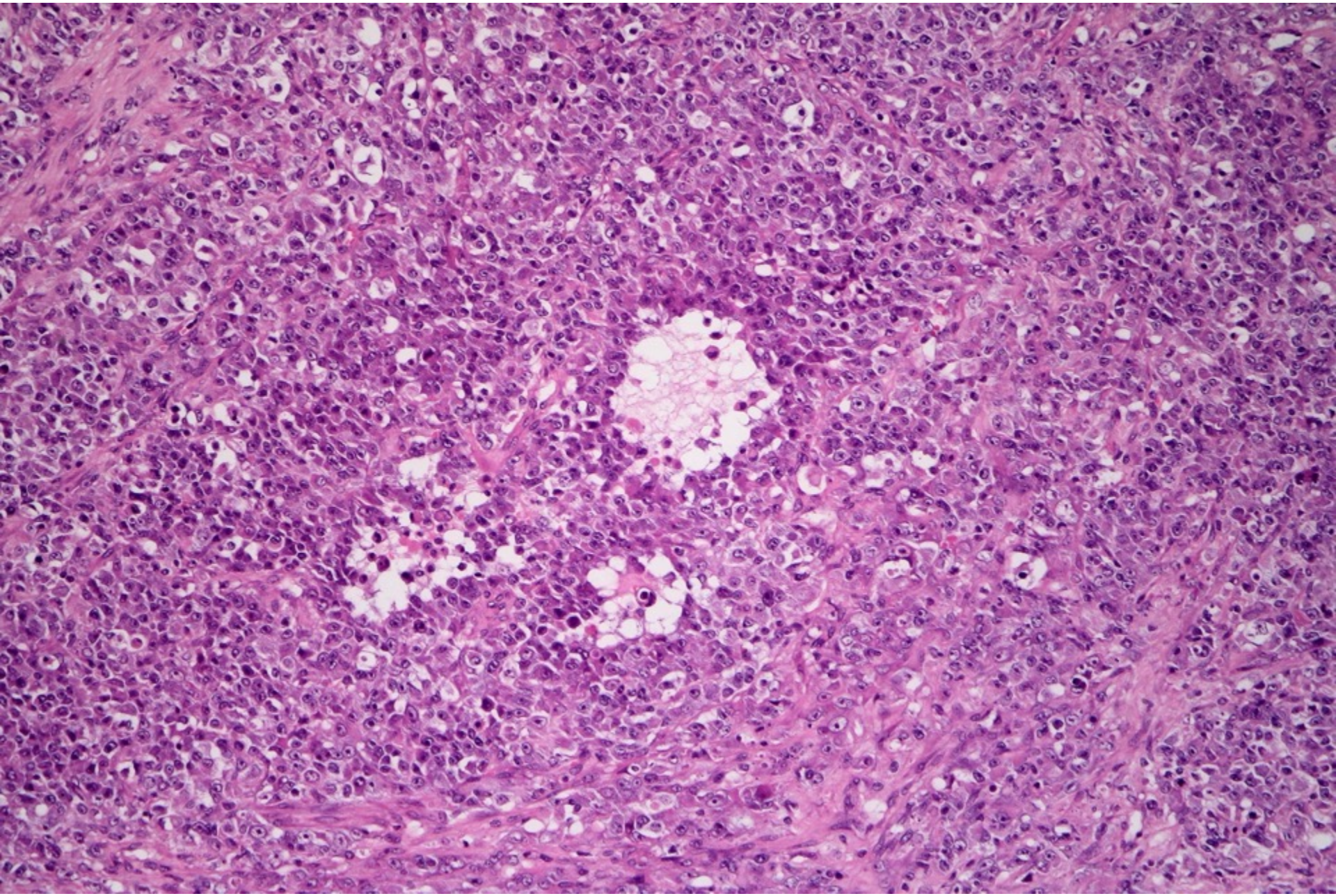

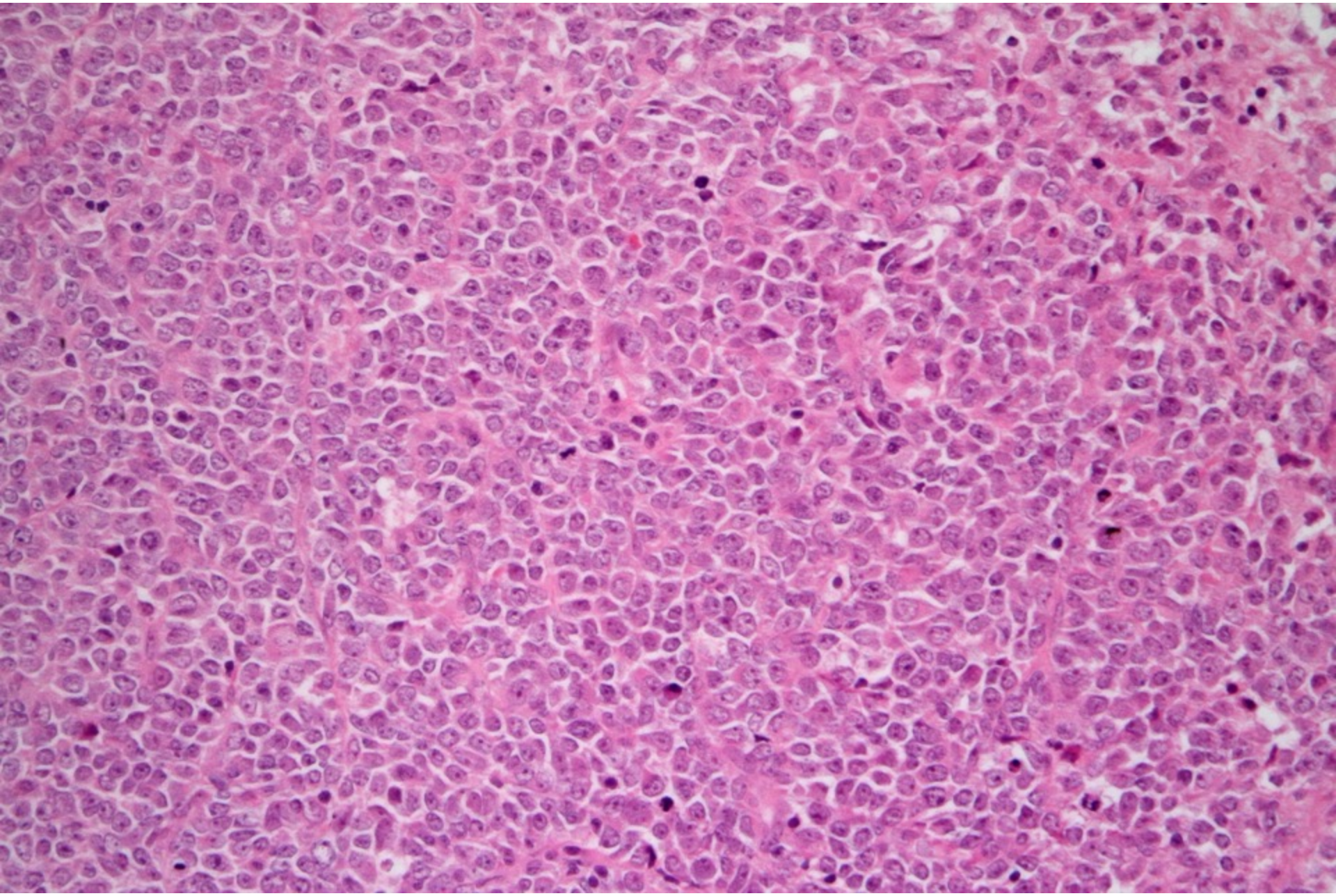

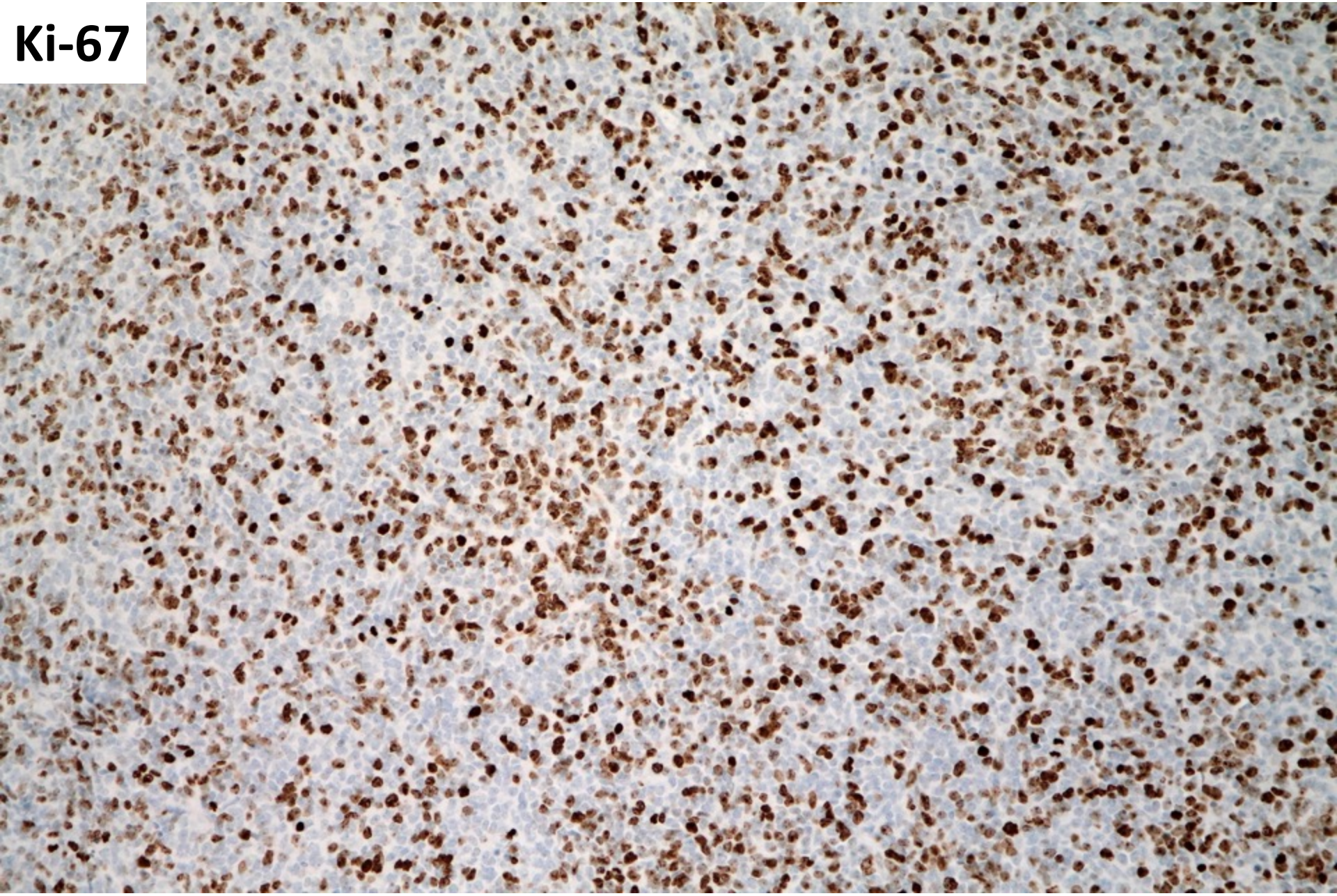
Ki-67

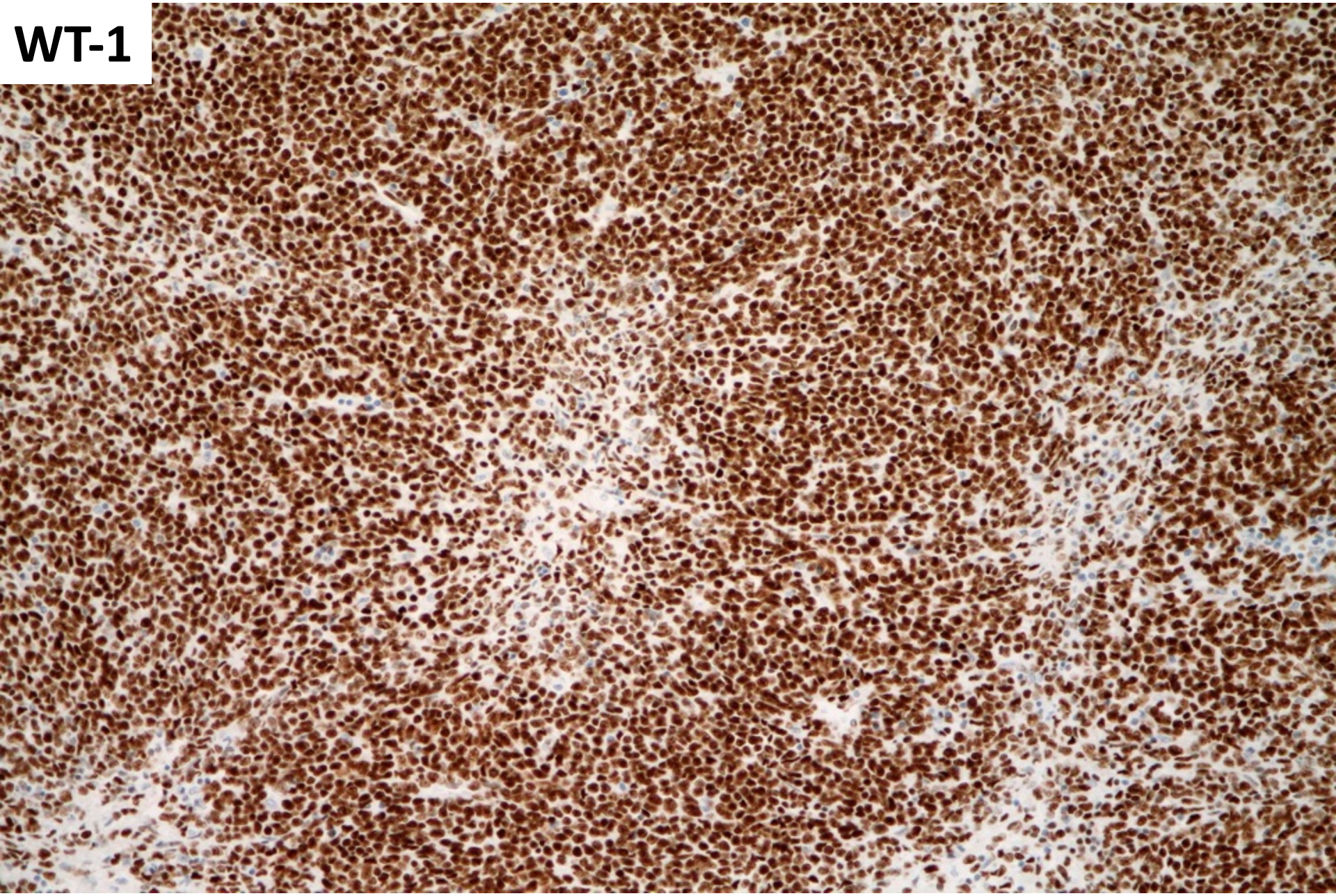
WT-1

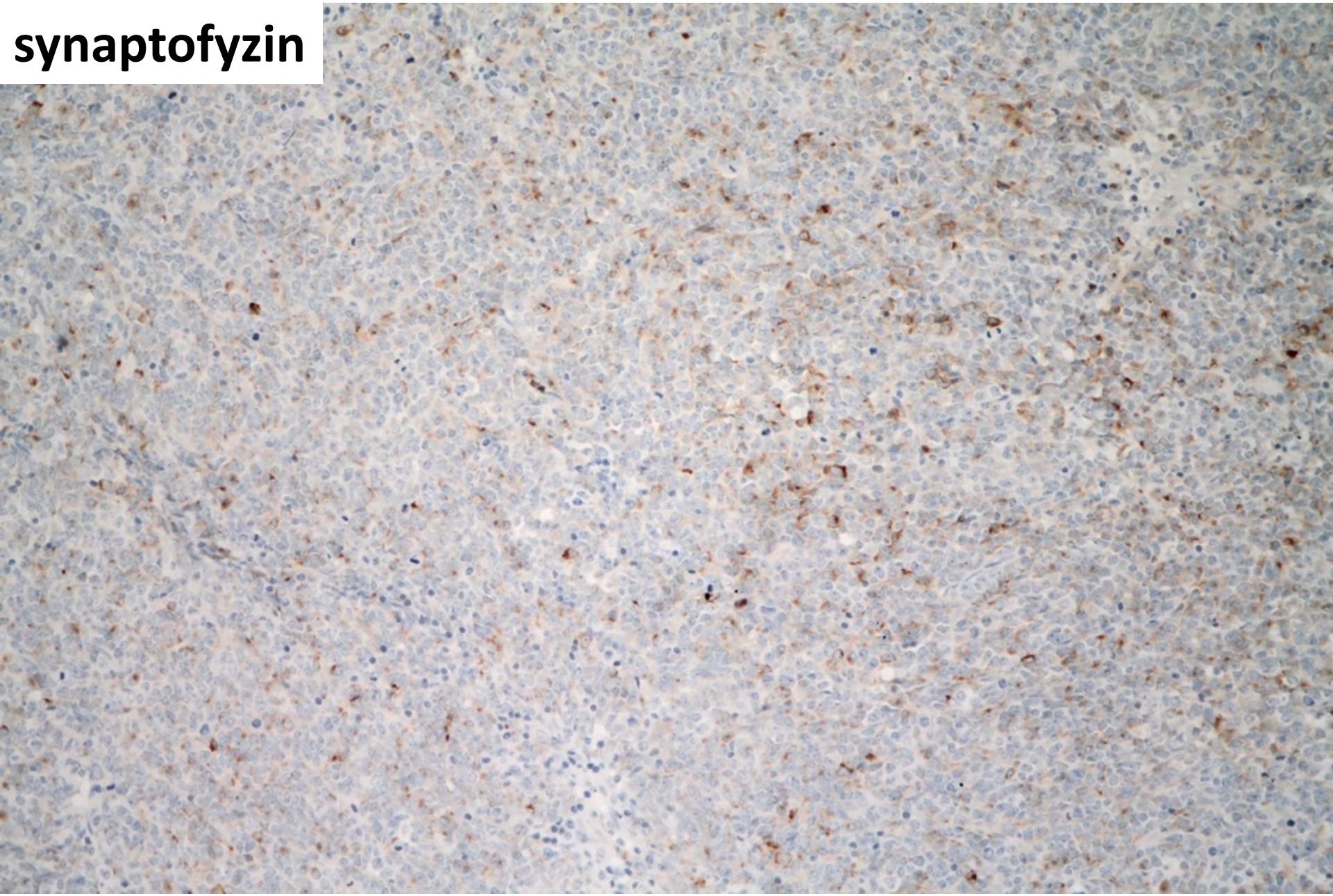
synaptofyzin

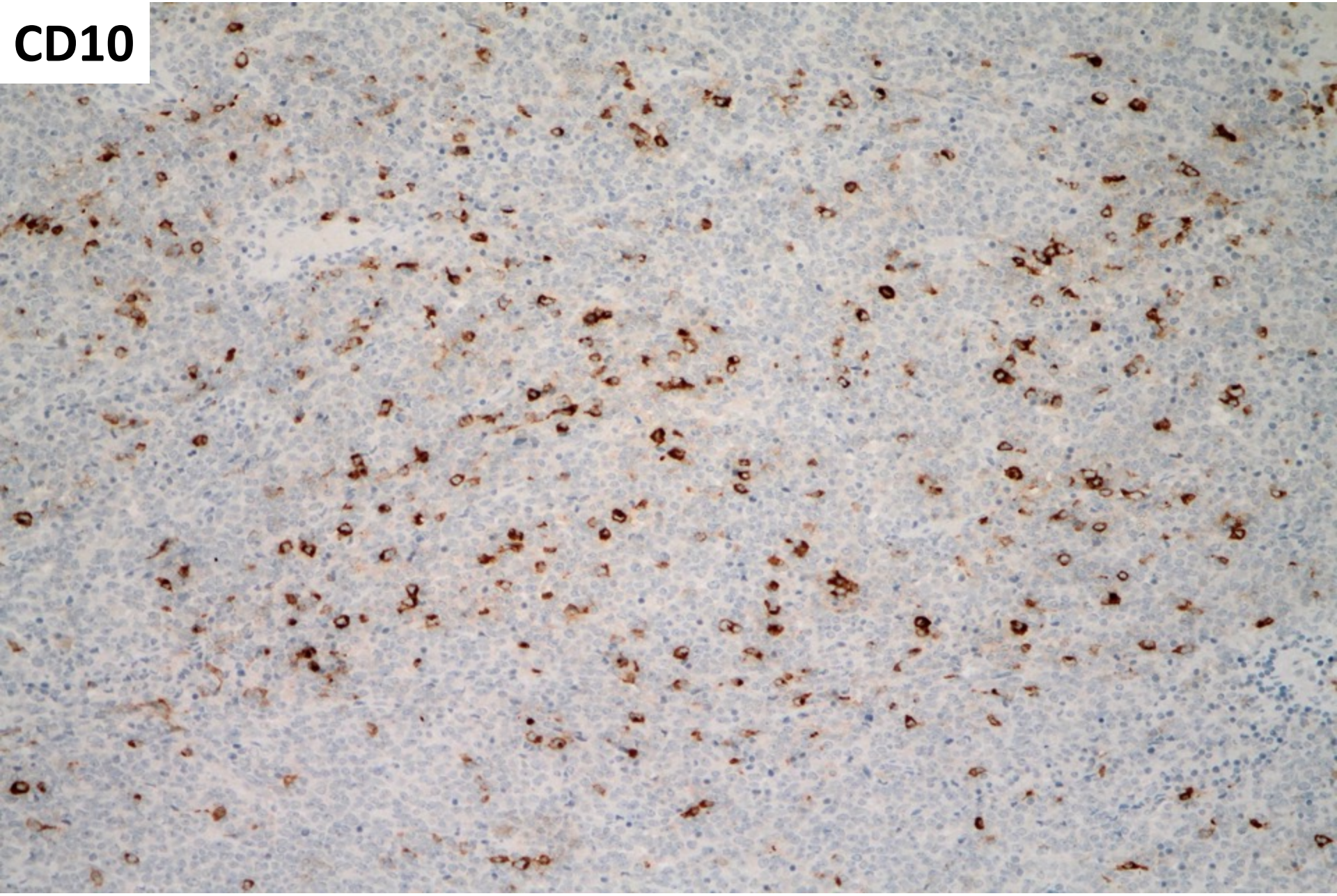
CD10

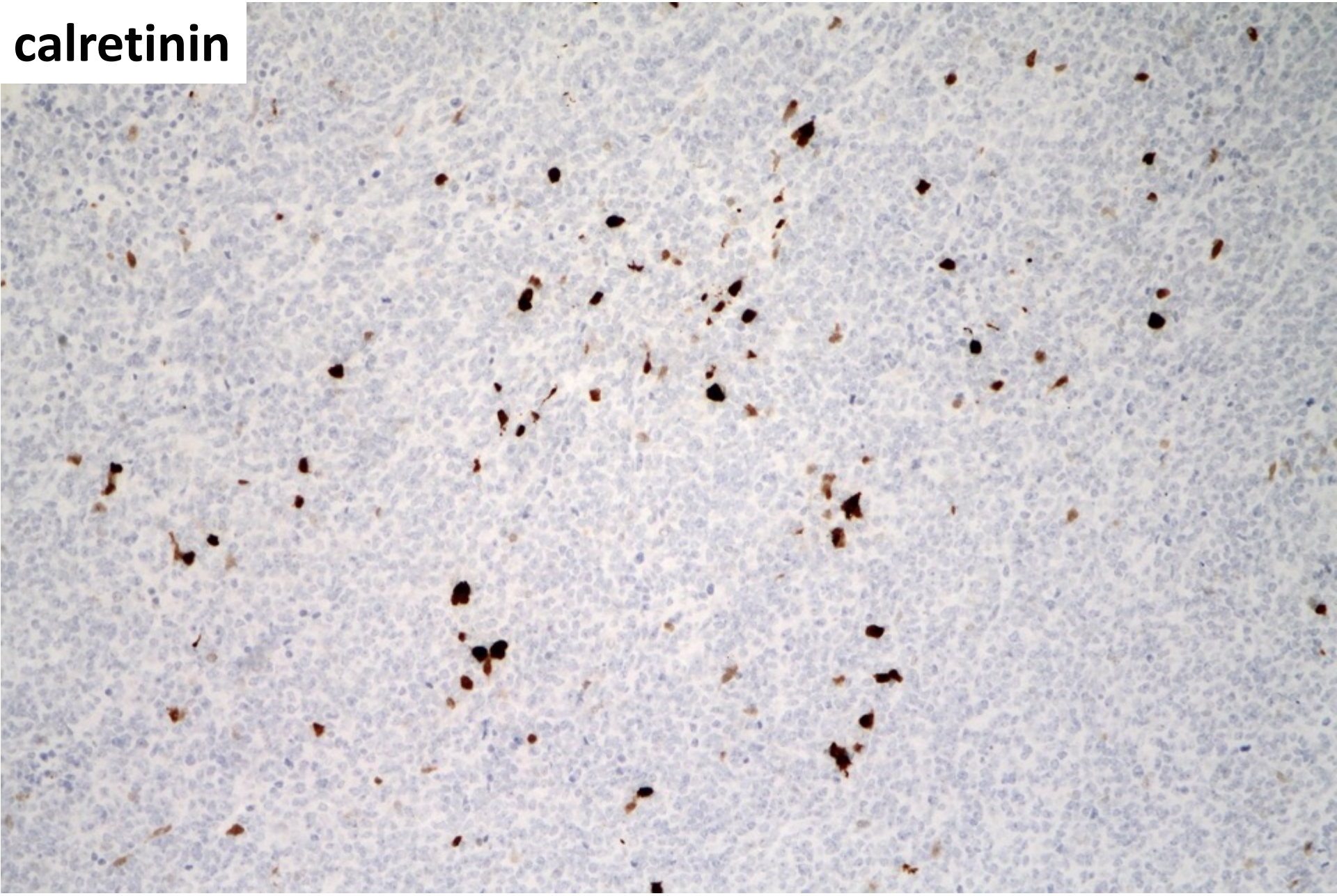
calretinin

případ č. 2
IHC shrnutí

- <u>pozitivní</u>
  - difúzně: WT-1
  - fokálně: synaptofyzin, CD10, calretinin, wt-p53
  - ojediněle: CK, PAX-8
- <u>negativní</u>
  - BER, MOC, CK7, EMA, claudin 4
  - chromogranin, CD56, INSM1
  - inhibin, SF1
  - SALL4
  - myoD1
  - GATA3, TTF1, CDX2
  - S100, SOX10, HMB-45, melan A

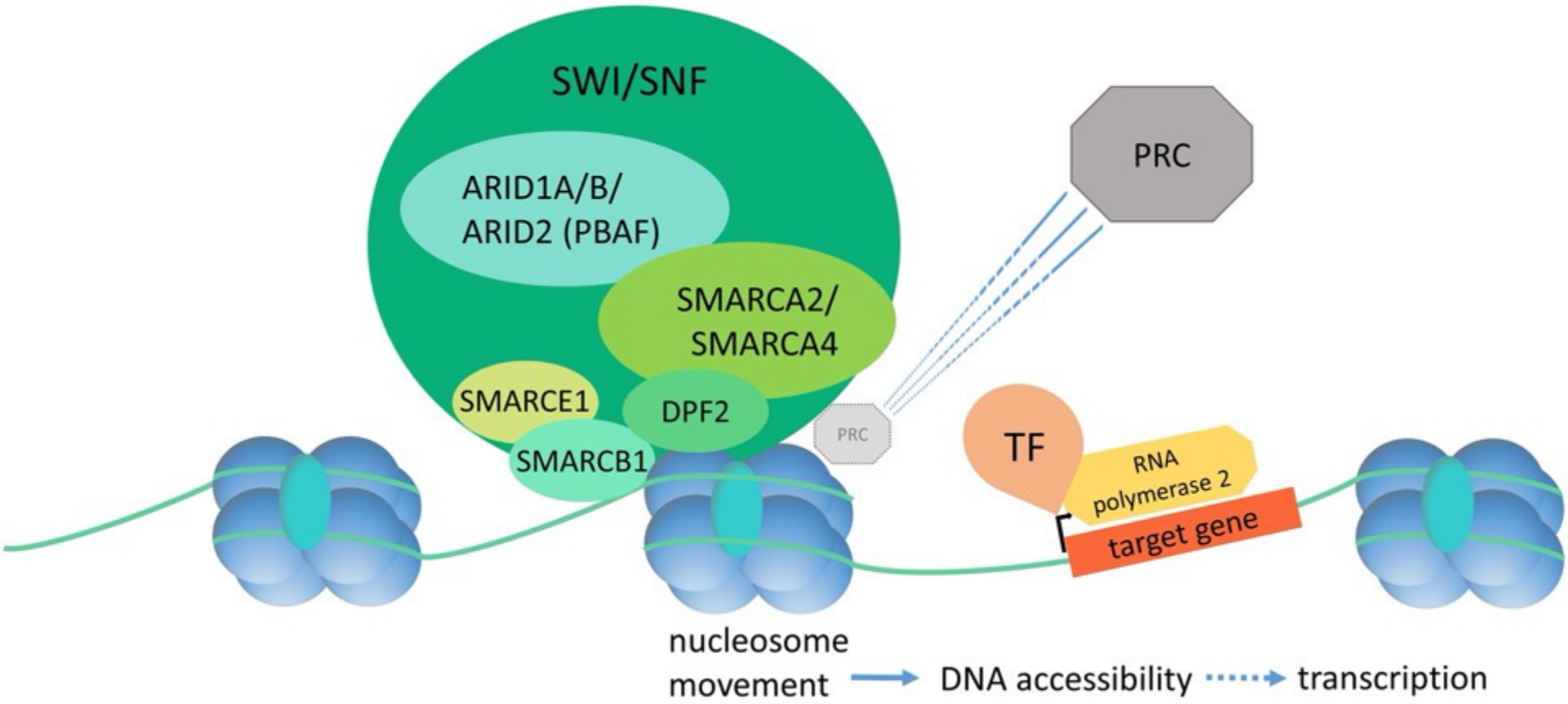

Bögershausen N et al. Front Mol Neurosci (2018)

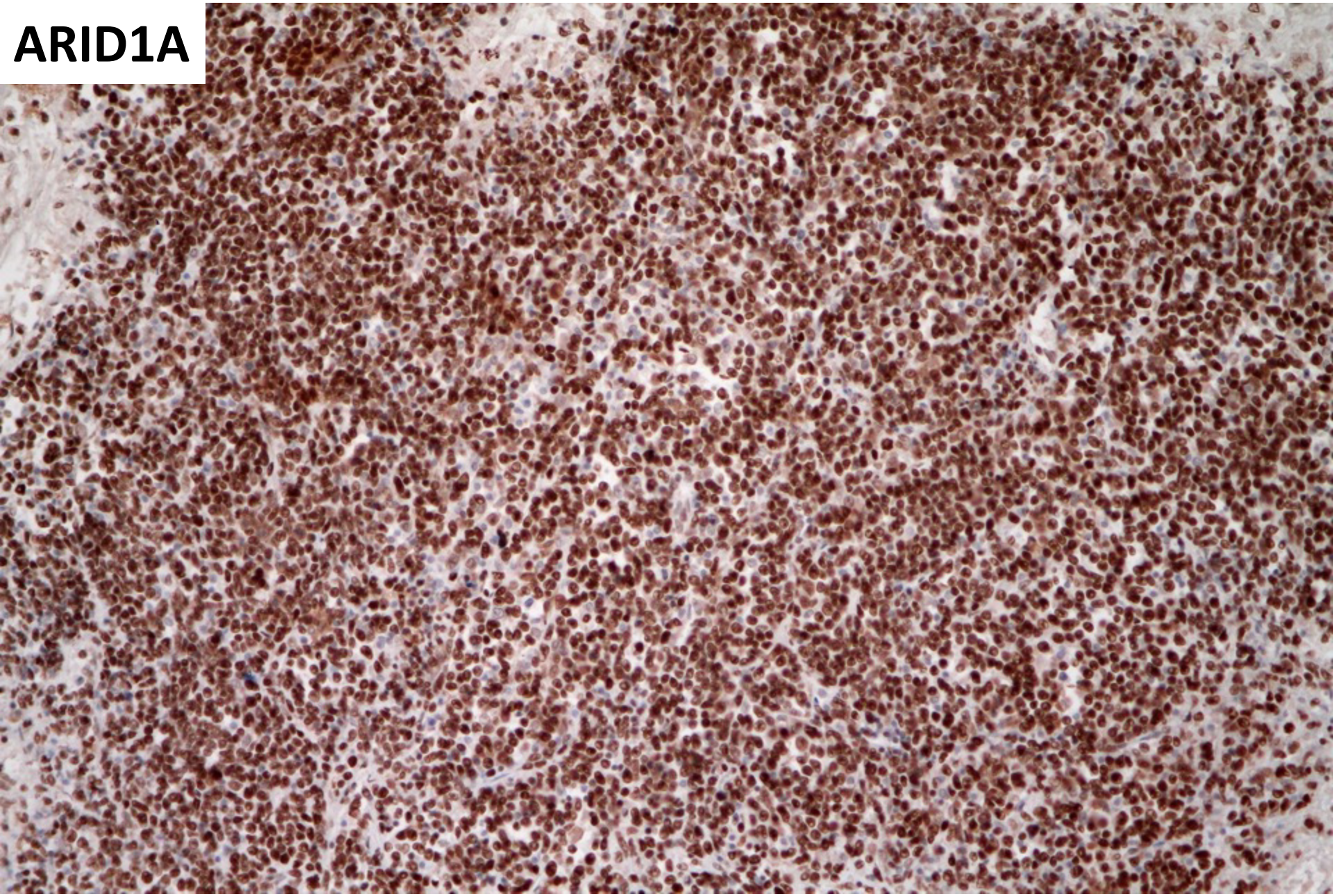
ARID1A

SMARCB1/INI1

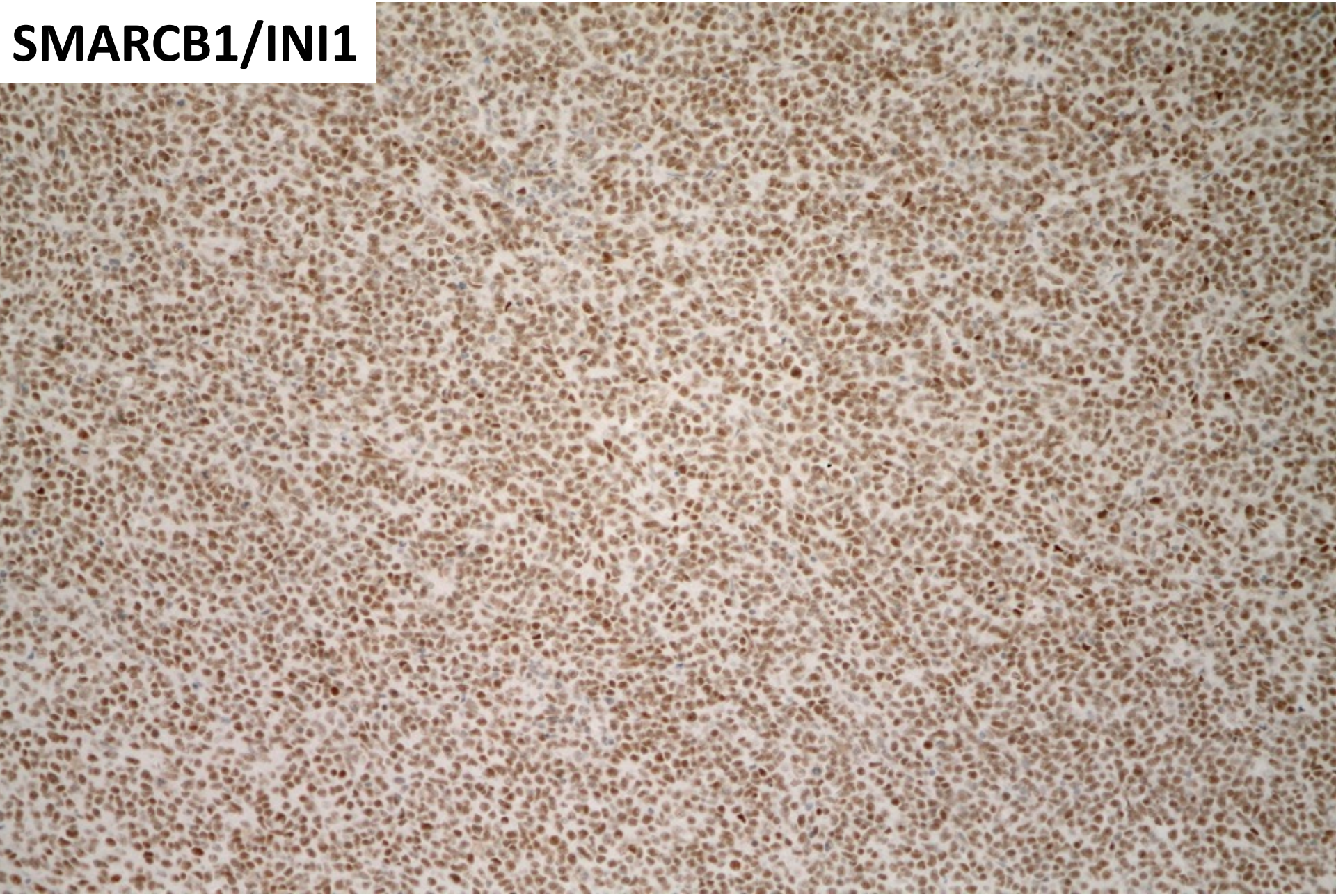

SMARCA4/BRG1

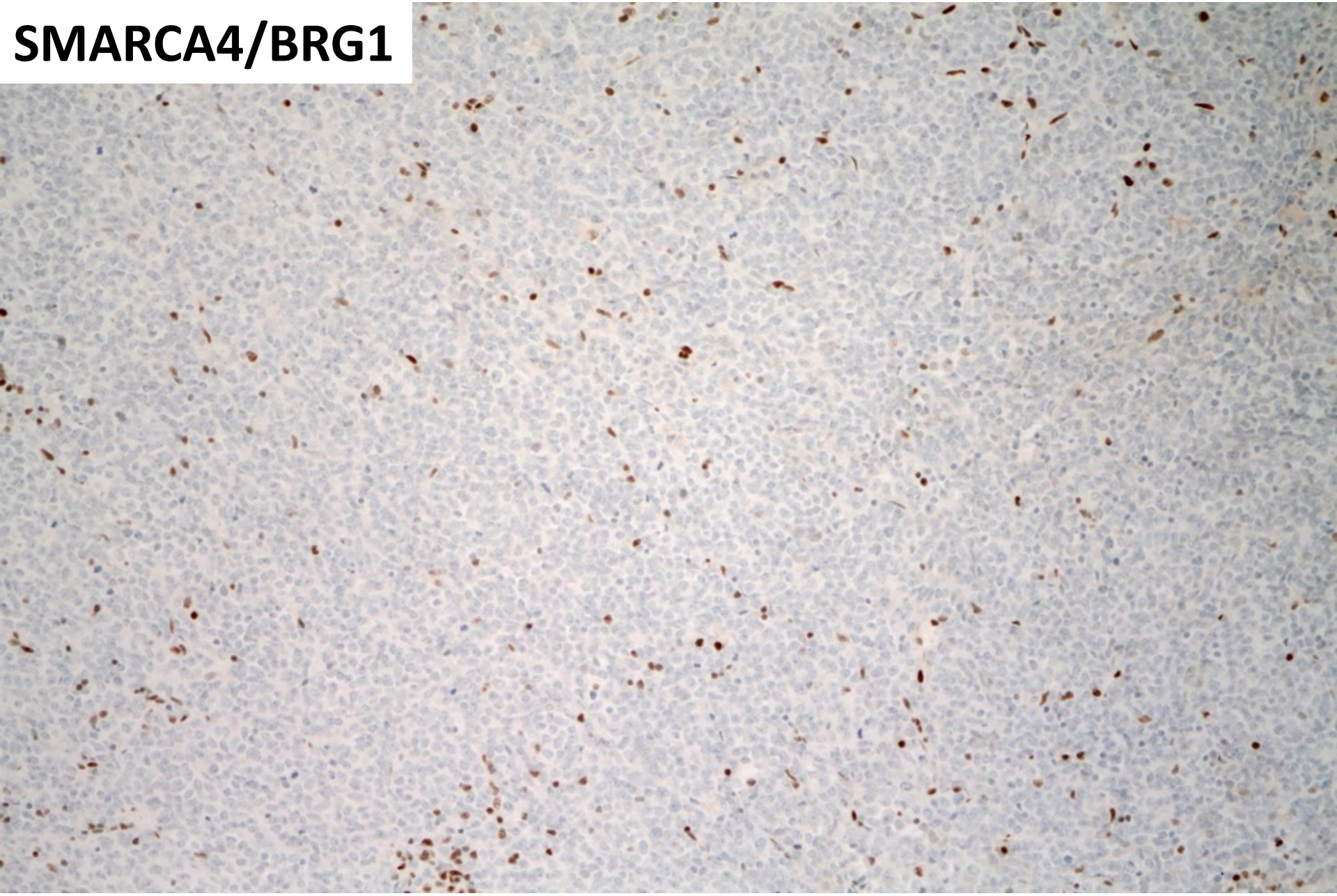

případ č. 2
Diagnóza

Malobuněčný karcinom ovaria, hyperkalcemický typ (velkobuněčný podtyp)

Malobuněčný karcinom ovaria, hyperkalcemický typ

- WHO 2020 – Miscellaneous tumours
  - „nediferencovaný tumor z malých ± velkých bb. ± hyperkalcémie (2/3)“
- < 1 % nádorů ovaria
- medián 25 let (9–43 le
- prognóza špatná

Small Cell Carcinoma of the Ovary with Hypercalcemia:

A Report of Eleven Cases

G. RICHARD DICKERSIN, MD., IRWIN W. KLINE, MD AND ROBERT E. SCULLY, MD

Eleven cases of a small cell ovarian cancer associated with hypercalcemia that was reversed by removal of the tumor are reported and compared with three similar cases in the literature. The 14 cases account for 50% of recorded cases of ovarian-cancer-related hypercalcemia. The 14 tumors occurred in women between the ages of 13 and 35, with an average of 22 years and, with two exceptions, behaved clinically in an aggressive fashion. Light and electron microscopic study confirmed the epithelial nature of the neoplasms but failed to disclose their specific subtype or origin.

Cancer 49:188–197, 1982.

Nat Genet. 2014 May ; 46(5): 427–429. doi:10.1038/ng.2928.

Small cell carcinoma of the ovary, hypercalcemic type, displays frequent inactivating germline and somatic mutations in *SMARCA4*

Pilar Ramos[1,2,15], Anthony N Karnezis[3,4,15], David W Craig[1], Aleksandar Sekulic[1,5], Megan L Russell[1], William P D Hendricks[1], Jason J Corneveaux[1], Michael T Barrett[1], Karey Shumansky[6], Yidong Yang[6], Sohrab P Shah[3,6], Leah M Prentice[4], Marco A Marra[7], Jeffrey Kiefer[1], Victoria L Zismann[1], Troy A McEachron[1], Bodour Salhia[1], Jaime Prat[8], Emanuela D'Angelo[8], Blaise A Clarke[9], Joseph G Pressey[10], John H Farley[11], Stephen P Anthony[12], Richard B S Roden[13], Heather E Cunliffe[1,14], David G Huntsman[3,4,16], and Jeffrey M Trent[1,16]

Nat Genet. 2014 May ; 46(5): 424–426. doi:10.1038/ng.2922.

Recurrent *SMARCA4* mutations in small cell carcinoma of the ovary

Petar Jelinic, et al.
Department of Surgery, Memorial Sloan-Kettering Cancer Center, New York, New York, USA

= maligní rhabdoidní tumor ovaria
± def.: somatická/germinální (40 % ?) mutace *SMARCA4* (> 95 %)
rhabdoid tumor predisposition syndrome 2 (AD)

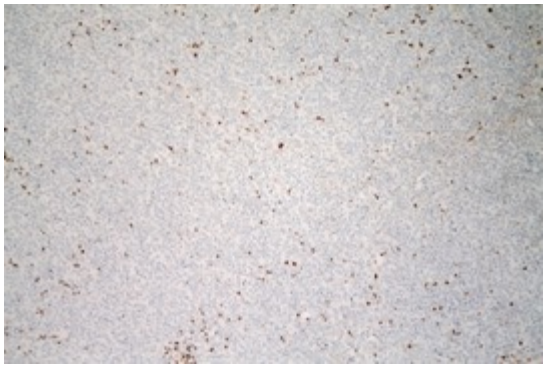

DOI: 10.5114/pjp.2013.39331 Pol J Pathol 2013; 64 (4): 238-2

Ovarian small cell carcinoma of hypercalcemic type – evidence of germline origin and *SMARCA4* gene inactivation. A pilot study

Jolanta Kupryjańczyk[1], Agnieszka Dansonka-Mieszkowska[1], Joanna Moes-Sosnowska[1], Joanna Plisiecka-Hałasa[1], Łukasz Szafron[1], Agnieszka Podgórska[1], Iwona K. Rzepecka[1], Bożena Konopka[1], Agnieszka Budziłowska[1], Alina Rembiszewska[1], Wiesława Grajkowska[2], Beata Śpiewankiewicz[3]

Germline and somatic *SMARCA4* mutations characterize small cell carcinoma of the ovary, hypercalcemic type

Leora Witkowski et al., *Nature Genetics* **vol 46**, 438–443 (2014)

Histopathology

Histopathology 2017, **70**, 1147–1154. DOI: 10.1111/his.13177

Clinical, morphological and immunohistochemical evidence that small-cell carcinoma of the ovary of hypercalcaemic type (SCCOHT) may be a primitive germ-cell neoplasm

W Glenn McCluggage,[1] Leora Witkowski,[2] Blaise A Clarke[3] & William D Foulkes[2]

[1]*Department of Pathology, Belfast Health and Social Care Trust, Belfast, Northern Ireland, UK,* [2]*Department of Human Genetics, McGill University, Montreal, Quebec, and* [3]*Department of Laboratory Medicine and Pathobiology, University of Toronto, University Health Network, Toronto, Ontario, Canada*

+ zralý teratom

+ nezralý teratom + YST

SALL4

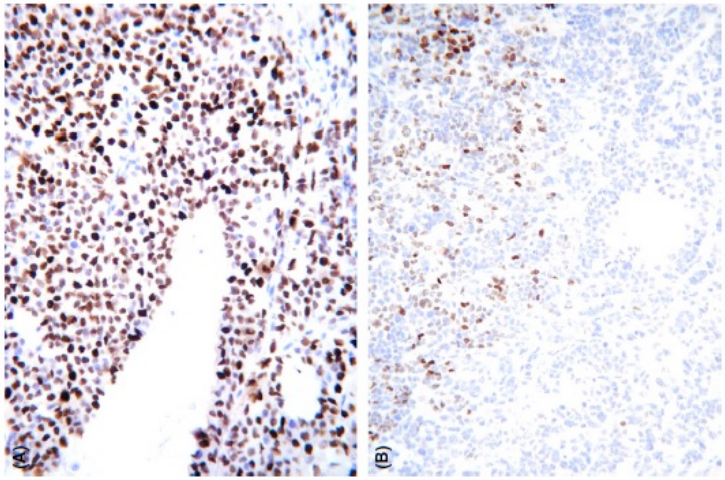

Malobuněčný karcinom ovaria, hyperkalcemický typ

- IHC:
  - **ztráta SMARCA4**/SMARCA2 + difúzně pozitivní WT1 (N-terminal)
  - variabilně: CK, EMA, claudin 4, CD10, CD99, **SALL4**, calretinin, NE markery
  - negativní: desmin, inhibin, S100, TTF1

- dif. dg.:
  - nádor z buněk granulózy (SMARCA4+)
  - SMARCA4-negativní nádory
    - světlobuněčný karcinom (15/360; 4 %)
    - maligní melanom

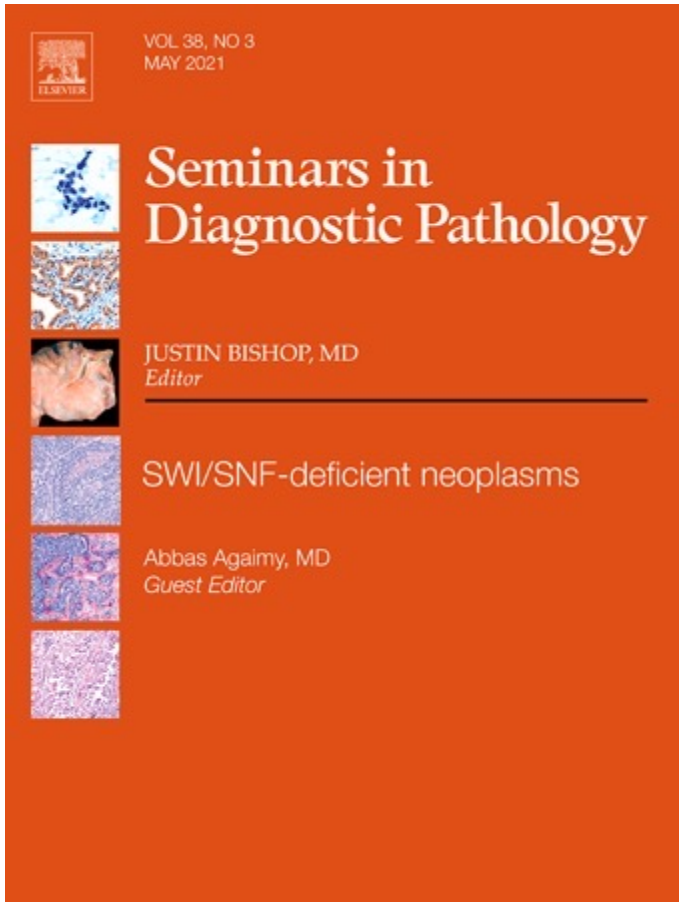

SMARCB1(INI-1)
SMARCA4 (BRG-1)

SMARCA2
ARID1A/B